

INTERNATIONAL CORNER: NUCLEAR CARDIOLOGY IN EUROPE – REVIEW ARTICLE

One Year of Nuclear Cardiology in France

Fayçal Ben Bouallègue, MD, PhD^{1,2)} and Denis Agostini, MD, PhD¹⁾

Received: April 13, 2017/Revised manuscript received: May 31, 2017/ Accepted: June 7, 2017

© The Japanese Society of Nuclear Cardiology 2017

Abstract

The present paper provides an overview of selected articles published by French research teams that are representative of recent advances in the field of nuclear cardiology, particularly in connection with the advent of new dedicated cardiac CZT cameras. The topics discussed here cover the impact of respiratory motion correction in myocardial perfusion imaging, global and regional LV function assessment using CZT cameras, innovative approaches in MIBG imaging, and RV function analysis by means of gated blood pool SPECT.

Keywords: CZT cameras, Gated blood pool SPECT, LV function, MIBG imaging, Myocardial perfusion

Ann Nucl Cardiol 2017 ; 3 (1) : 192–196

Owing to its non-invasive, cost-effective, and widely available nature, nuclear cardiology has long become an essential tool for diagnostic and prognostic purposes in numerous cardiovascular diseases, especially coronary artery disease (CAD). It has benefited these last years from the sustained development of advanced technologies, both in terms of equipment and software solutions. In particular, the advent of solid state detectors cameras using CZT semi-conductors has substantially boosted the research prospects in many areas of nuclear cardiology, including myocardial perfusion imaging (MPI), MIBG imaging, and gated blood pool SPECT. The present paper provides an overview of selected articles representative of recent advances in the field of nuclear cardiology published these last months by French research teams.

Respiratory motion correction in MPI

Recently, a new generation of dedicated cardiac CZT SPECT gamma cameras has been commercialized. These cameras offer higher count sensitivity and spatial resolution with comparison to classical Anger cameras, allowing faster myocardial perfusion imaging protocols and significant reduction in injected activities (1, 2) (see Fig. 1). In addition, data are acquired dynamically in list-mode synchronized to ECG, opening the way to easier handling of patient motion.

Respiratory motion (RM) of the thoraco-abdominal organs may introduce blurring and artefacts into the images and impact MPI performances. RM correction is thus desirable in order to fully benefit from the high spatial resolution of CZT systems. In this context, Daou et al. proposed an innovative data-driven method for RM correction and studied its impact on the extent and severity of myocardial perfusion defects observed with free-breathing CZT SPECT (3-5).

The proposed method relied on the rebinning of list-mode data to generate a dynamic SPECT acquisition consisting of 500 ms time frames over 5 minutes. Dynamic images were post-processed to produce a data-driven RM curve using a statistical method adapted to low signal-to-noise ratio data. RM gated images were then reconstructed and summed after rigid realignment based on normalized cross-correlation (3). The technique was validated in 25 patients with known or suspected CAD having a 1-day ^{99m}Tc-tetrofosmin stress/rest MPI using a Discovery NM 530c camera (5). Tracer uptake was rated using both visual and semi-quantitative analyses and RM correction was considered as having an impact if at least one myocardial segment presented a severity score changing by at least one level. Cardiac RM was significant in most of the MPI studies, especially in male patients and in stress acquisitions, and predominated along the anterior-inferior axis. RM correction had an impact on qualitative and

doi: 10.17996/anc.17-00017

1) Fayçal Ben Bouallègue, Denis Agostini
Caen University Hospital, Nuclear Medicine Department, Avenue de la Côte de Nacre, 14033, Caen, France
E-mail: faybenb@hotmail.com

2) Fayçal Ben Bouallègue
Montpellier University Hospital, Nuclear Medicine Department, Montpellier, France

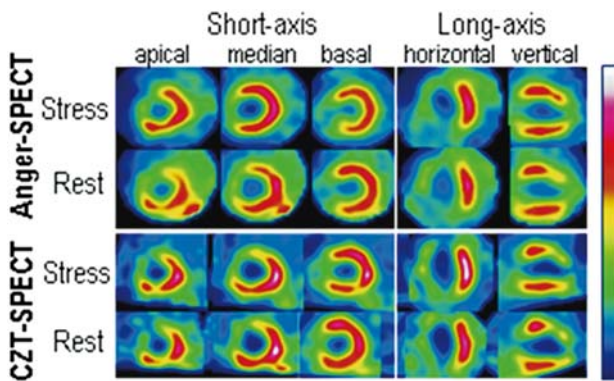


Fig. 1 Detection of a myocardial infarction using (top) classical Anger camera and (bottom) dedicated CZT camera. A fixed septo-apical defect is viewed using both cameras. Owing to its higher spatial resolution, the area of the infarct zone detected using the CZT camera is wider than using the Anger camera, with an extension to the antero-septal segment (Courtesy of Nancy University Hospital, France).

quantitative interpretation in 14% of all studies (7/49) and in 60% of studies with cardiac RM greater than 15 mm. In the majority of these studies, the extent and severity of perfusion defects was decreased compared to non-corrected data, most frequently in the inferior wall. Further investigations focusing on the subgroup of patient with substantial cardiac RM remain necessary to fully elucidate the clinical yield of RM compensation in terms of diagnostic and therapeutic management. The authors also raised the need to evolve the method to double ECG and respiratory gating by integrating RM correction directly in the reconstruction process of CZT SPECT.

LV function assessment using CZT cameras

Measurement of left ventricular (LV) ejection fraction (EF), end-diastolic volume (EDV) and end-systolic volume (ESV) using gated myocardial SPECT has been widely validated in comparison to other imaging techniques and is commonly used for prognosis assessment and clinical decision making (6). LV function assessment also includes evaluation of regional LV wall motion and thickening based on differential count density induced by partial volume effect (PVE) between end-diastolic and end-systolic images (7). Claudin et al. demonstrated that LV function assessed on a CZT camera, with low injected activities and limited recording times, correlates well with the reference assessment from cardiac magnetic resonance (CMR) (8). Seventy-six patients with known or suspected CAD undergone CMR and stress/rest MPI with a target of 500 myocardial kcounts in order to limit the recording times (<10 minutes for stress, <4 minutes for rest). SPECT images were reconstructed with a method maintaining high spatial (8 mm) and temporal (16 frames/cycle) resolutions. Correlation between CZT-SPECT and CMR were good to excellent for LV EF ($r=0.88$), EDV ($r=0.94$) and ESV

($r=0.96$), and segmental contractility correlated well between the two techniques ($\kappa=0.72$). In another study, Blaire et al. showed that global and segmental LV function assessment was also feasible using $^{99m}\text{Tc}/^{123}\text{I}$ dual-isotope acquisitions (9). A dynamic cardiac phantom was imaged using two commercially available CZT cameras (DNM 530c, GE Healthcare, and D-SPECT, Spectrum Dynamics) and scatter, cross-talk, and tailing effect corrections were applied when available. Owing to the high energy resolution associated with CZT detectors, there was an excellent correlation and no significant difference between single and dual-isotope studies in terms of LV volumes, EF, and wall motion.

Bailliez et al. studied the impact of new CZT cameras on global and regional LV function assessment using phantom and patient data (10, 11). In (10), LV volumes and EF measurements were compared using two CZT cameras (DNM 530c and D-SPECT) and a multipurpose camera equipped with multifocal collimators (IQ-SPECT, Siemens Healthcare). In the gated dynamic cardiac phantom study, volumes were higher for the CZT cameras than for the conventional camera, resulting in a decreased but more accurate LV EF estimates. In clinical data from 120 patients with low pre-test likelihood of CAD and normal findings on stress perfusion SPECT, body-surface-indexed volumes were higher for the DNM 530c than for the D-SPECT and the IQ-SPECT, resulting in a significantly decreased LV EF values. The effect of the type of camera on global function was likely related to spatial resolution which is 6.7 mm for the DNM, 8.6 mm for the D-SPECT, and 15 mm for the IQ-SPECT (12). When the end-systolic cavity size approaches the spatial resolution of the system, PVE induces blurring at the myocardial wall edges and miscalculation of the endocardial surface. The increased spatial resolution of CZT-based cameras, by minimizing PVE, results in increased volume measurements.

In (11), a phantom study evaluated the accuracy of wall thickening assessment on both Anger and CZT (DNM 530c) cameras, then CZT gated SPECT was compared to CMR in 27 patients. In both the phantom and patients, the increase in spatial resolution provided by the CZT camera had a negative impact on the assessment of myocardial wall thickening, especially in hypertrophic conditions. In patients, CZT SPECT underestimated the regional wall thickening compared to CMR, with a fair correlation between the two techniques. This underestimation was substantial in patients with myocardial thickness greater than twice the resolution of the CZT camera (i.e., >12 mm). CMR and CZT SPECT wall motions were fairly correlated and the difference between the two techniques was not dependent on the amplitude of wall motion. Wall motion may thus be a better tool than wall thickening for routine assessment of segmental LV function using CZT cameras in patients with hypertrophic cardiomyopathy.

Prospects in MIBG imaging

¹²³I-MIBG imaging is recognized as an independent prognostic factor in patients with heart failure and has been shown to be predictive of ventricular arrhythmia after myocardial infarction (13, 14). In 2016, the first joint session of the Japanese and American Societies of Nuclear Cardiology has emphasized the clinical usefulness of ¹²³I-MIBG and the need for standardized procedures (15). These last decades, cardiac denervation has been assessed using heart-to-mediastinum-ratio (HMR) and wash-out rate derived from planar imaging. The advent of CZT cameras opens the way to more accurate measurements of regional myocardial sympathetic innervation and allows for easier dual-isotope imaging, but still require substantial standardization effort. Bellevre et al. compared late HMR measurements computed from planar images acquired using an Anger camera and front view D-SPECT cine data in a phantom study and 44 patients with heart failure (16). In the phantom study, HMR values were significantly higher using D-SPECT than using Anger camera (2.21 ± 0.70 vs 1.77 ± 0.42 , $p=0.02$). The correlation between the two distributions was excellent ($r=0.98$), allowing to determine a regression equation used for calculating D-SPECT corrected HMRs. The authors hypothesized that the higher energy discrimination and lower amount of scattered photons using D-SPECT may lead to a better image contrast on MIBG scans, hence an increase in HMR. In the patient population, Anger and corrected D-SPECT HMRs were highly concordant (Lin's coefficient 0.89) and in close agreement over the whole range of HMR values. Further studies are needed to standardize the placement of the mediastinal region of interest using the different CZT cameras available.

In patients with myocardial infarction, myocardial viability and sympathetic innervation may be evaluated simultaneously using dual-isotope ²⁰¹Tl/¹²³I-MIBG imaging. This technique does not require image registration, reduces the time of the acquisition protocol, improves patient comfort, and is compatible with trigger zone (i. e., areas of viable but denervated myocardium) assessment in routine clinical settings. D'estanque et al. evaluated the necessity of delayed acquisition and scatter correction for dual isotope CZT SPECT to detect trigger zones in 69 patients after revascularization (17). Areas of myocardium with impaired innervation were significantly higher on late than on early MIBG images, confirming the need for late MIBG acquisition. Scarred myocardial surface was significantly greater on scatter-corrected than on non-scatter-corrected ²⁰¹Tl images, yielding better agreement with reference CMR or echocardiographic data (72% sensitivity, 91% specificity). As a consequence, the extent of trigger zones (mismatch between perfusion and MIBG defects) decreased significantly after scatter-correction. Patient follow-up is ongoing to determine whether

trigger zone quantification using dual-isotope SPECT has a predictive value regarding rhythmic events.

Another potential application of MIBG imaging lies in the evaluation of the area at risk after myocardial infarction, which is mainly determined by the duration of ischemia and the presence of collateral flow. The angiographic modified APPROACH score is usually used to assess the area at risk, assuming that the proportion of left myocardium jeopardized during an acute myocardial infarction is dependent on the length and size of the branches of the culprit coronary artery only, without taking into account the other coronary lesions, the collateral flow, or the residual flow in the culprit artery. Vauchot et al. performed MIBG imaging in 70 patients 12 ± 10 days after myocardial infarction and computed a 17-segment summed rest score (SRS) of relative myocardial uptake (18). In 50 patients with an occluded culprit artery, the SRS was highly correlated with the APPROACH score ($r=0.76$), even after stratification by CAD severity and LV function. There was a good agreement between the two methods in terms of percentage of jeopardized myocardium and both methods identified the same myocardial walls as area at risk for all 50 patient. In 20 patients with a sub-occluded artery, for which the angiographic score is known to be inaccurate, MIBG and APPROACH scores were little correlated ($r=0.18$), likely due to the residual flow in the culprit artery. The specific insight into area at risk provided by MIBG SPECT could help cardiologists in their revascularization strategies, which is currently a bone of contention in the interventional field, particularly when APPROACH is inappropriate or inaccurate.

Gated blood pool SPECT

Gated blood pool SPECT allows for simultaneous evaluation of bi-ventricular function and has been widely validated for LV function analysis. Right ventricle (RV) function assessment is clinically relevant because it can independently determine prognosis, treatment, and follow-up in a wide range of indications (19). Yet, it remains a challenge, with specific issues related to the modelling of the RV shape, the delineation of the outflow tract, and the definition of the valve planes. Dercle et al. systematically compared the performances of three available software (BP-SPECT, QBS, and TomPool) in 48 patients in order to define optimal threshold values for RV impairment detection (20). Compared to CMR and thermodilution as gold-standards for RV volume/EF and cardiac output respectively, the respective optimal thresholds for the three software were 54.7%, 38.5%, and 45.2% (AUC: 0.83, 0.80, 0.79) for RV EF, 229, 180, and 94 mL (AUC: 0.83, 0.81, 0.81) for RV EDV, and 4.1, 4.4, and 2.6 L/minute (AUC: 0.73, 0.77, 0.80) for cardiac output. Differences between post-processing tools may be explained by several factors including the segmentation method (gradient-based vs

watershed), the volume computation method (surface-based vs count-based), the number of time frames (8 vs 16), the type of fit (multi-harmonic vs template-based), and the delineation of the valves plane (automatic vs manual). These significant inter-algorithm differences stress the need for CMR-based calibration before quantitative analysis of the RV in clinical routine.

Assessment and follow-up of bi-ventricular volumes is a key point in the management of patients with left ventricular assist devices (LVAD) (21). Because the RV is not assisted, its function is a critical determinant of the hemodynamic and contributes significantly to postoperative morbidity and mortality. Yet, usual imaging techniques including echocardiography, multi-detector computed tomography (MDCT), and planar radionuclide ventriculography are of limited feasibility due to artefacts induced by the LVAD (22). Lairez et al. evaluated the feasibility and accuracy of gated blood pool SPECT in 24 patients with LVAD, with a peculiar attention to RV function assessment (23). In 9 patients who underwent an MDCT, correlation with SPECT measurements was significant for RV EDV ($r=0.73$), ESV ($r=0.88$), and EF ($r=0.78$). A cut-off value of 40% for RV EF measured by SPECT could discriminate patients with poor functional status ($p=0.05$ for NYHA stage, $p=0.02$ for the six-minute walk test, and $p=0.01$ for peak oxygen consumption). Due to count-based measurement of ventricular functions, quantitation using gated blood pool SPECT does not depend on mathematical assumptions regarding ventricular geometry, allowing high reproducibility and serial monitoring. These results warrant its widespread use for initial assessment and monitoring of patients with LVAD.

Conclusion

The advent of new CZT cameras dedicated for cardiac explorations is undoubtedly the most striking recent advance in the field of nuclear cardiology. The optimisation and standardization of acquisition protocols and image post-processing methods should increase patient comfort and allow significant improvement in image quality. French research teams have made a substantial contribution toward these goals. Work is under way to corroborate the long-term clinical benefit of state-of-the art techniques in myocardial perfusion quantification, MIBG imaging, and gated blood pool SPECT.

Acknowledgments

None.

Sources of funding

None.

Conflicts of interest

None.

Reprint requests and correspondence:

Fayçal Ben Bouallègue, MD, PhD

Caen University Hospital, Nuclear Medicine Department,
Avenue de la Côte de Nacre, 14033, Caen, France

E-mail: faybenb@hotmail.com

References

1. Slomka PJ, Berman DS, Germano G. New cardiac cameras: single-photon emission CT and PET. *Semin Nucl Med* 2014; 44: 232-51.
2. Agostini D, Marie PY, Ben-Haim S, et al. Performance of cardiac cadmium-zinc-telluride gamma camera imaging in coronary artery disease: a review from the cardiovascular committee of the European Association of Nuclear Medicine (EANM). *Eur J Nucl Med Mol Imaging* 2016; 43: 2423-32.
3. Daou D, Sabbah R, Coaguila C, et al. Feasibility of data-driven cardiac respiratory motion correction of myocardial perfusion CZT SPECT: A pilot study. *J Nucl Cardiol* 2016. [Epub ahead of print]
4. Daou D, Sabbah R, Coaguila C, et al. Applicability of data-driven respiratory motion correction to CZT SPECT myocardial perfusion imaging in the clinical setting: The birth of an old wish. *J Nucl Cardiol* 2016. [Epub ahead of print]
5. Daou D, Sabbah R, Coaguila C, et al. Impact of data-driven cardiac respiratory motion correction on the extent and severity of myocardial perfusion defects with free-breathing CZT SPECT. *J Nucl Cardiol* 2017. [Epub ahead of print]
6. Thomas GS, Miyamoto MI, Morello AP 3rd, et al. Technetium ^{99m} sestamibi myocardial perfusion imaging predicts clinical outcome in the community outpatient setting. The Nuclear Utility in the Community (NUC) Study. *J Am Coll Cardiol* 2004; 43: 213-23.
7. Noordzij W, Slart R. Clinical value of quantitative measurements derived from GATED SPECT: motion and thickening, volumes and related LVEF. *Q J Nucl Med Mol Imaging* 2016. [Epub ahead of print]
8. Claudin M, Imbert L, Djaballah W, et al. Routine evaluation of left ventricular function using CZT-SPECT, with low injected activities and limited recording times. *J Nucl Cardiol* 2016. [Epub ahead of print]
9. Blaire T, Bailliez A, Bouallègue FB, et al. Left ventricular function assessment using ^{123I}/^{99mTc} dual-isotope acquisition with two semi-conductor cadmium-zinc-telluride (CZT) cameras: a gated cardiac phantom study. *EJNMMI Phys* 2016; 3: 27.
10. Bailliez A, Lairez O, Merlin C, et al. Left ventricular function assessment using 2 different cadmium-zinc-telluride cameras compared with a γ -camera with cardiofocal collimators: dynamic cardiac phantom study and clinical validation. *J Nucl Med* 2016; 57: 1370-5.
11. Bailliez A, Blaire T, Mouquet F, et al. Segmental and global left ventricular function assessment using gated SPECT with a semiconductor Cadmium Zinc Telluride (CZT) camera: phantom study and clinical validation vs cardiac magnetic resonance. *J Nucl Cardiol* 2014; 21: 712-22.

12. Imbert L, Poussier S, Franken PR, et al. Compared performance of high-sensitivity cameras dedicated to myocardial perfusion SPECT: a comprehensive analysis of phantom and human images. *J Nucl Med* 2012; 53: 1897-903.
13. Jacobson AF, Senior R, Cerqueira MD, et al. Myocardial iodine-123 meta-iodobenzylguanidine imaging and cardiac events in heart failure. Results of the prospective ADMIRE-HF (AdreView Myocardial Imaging for Risk Evaluation in Heart Failure) study. *J Am Coll Cardiol* 2010; 55: 2212-21.
14. Boogers MJ, Borleffs CJ, Henneman MM, et al. Cardiac sympathetic denervation assessed with ¹²³I-iodine metaiodobenzylguanidine imaging predicts ventricular arrhythmias in implantable cardioverter-defibrillator patients. *J Am Coll Cardiol* 2010; 55: 2769-77.
15. Nakajima K, Scholte AJ, Nakata T, et al. Cardiac sympathetic nervous system imaging with ¹²³I-meta-iodobenzylguanidine: Perspectives from Japan and Europe. *J Nucl Cardiol* 2017. [Epub ahead of print]
16. Bellevre D, Manrique A, Legallois D, et al. First determination of the heart-to-mediastinum ratio using cardiac dual isotope (¹²³I-MIBG/^{99m}Tc-tetrofosmin) CZT imaging in patients with heart failure: the ADRECARD study. *Eur J Nucl Med Mol Imaging* 2015; 42: 1912-9.
17. D'estanque E, Hedon C, Lattuca B, et al. Optimization of a simultaneous dual-isotope ²⁰¹Tl/¹²³I-MIBG myocardial SPECT imaging protocol with a CZT camera for trigger zone assessment after myocardial infarction for routine clinical settings: Are delayed acquisition and scatter correction necessary? *J Nucl Cardiol* 2016. [Epub ahead of print]
18. Vauchot F, Ben Bouallègue F, Hedon C, et al. Assessment of the area at risk after acute myocardial infarction using ¹²³I-MIBG SPECT: Comparison with the angiographic APPROACH-score. *J Nucl Cardiol* 2016. [Epub ahead of print]
19. Hesse B, Lindhardt TB, Acampa W, et al. EANM/ESC guidelines for radionuclide imaging of cardiac function. *Eur J Nucl Med Mol Imaging* 2008; 35: 851-85.
20. Dercle L, Ouali M, Pascal P, et al. Gated blood pool SPECT: The estimation of right ventricular volume and function is algorithm dependent in a clinical setting. *J Nucl Cardiol* 2015; 22: 483-92.
21. Frazier OH, Baldwin AC, Demirozu ZT, et al. Ventricular reconditioning and pump explantation in patients supported by continuous-flow left ventricular assist devices. *J Heart Lung Transplant* 2015; 34: 766-72.
22. Hayek S, Sims DB, Markham DW, et al. Assessment of right ventricular function in left ventricular assist device candidates. *Circ Cardiovasc Imaging* 2014; 7: 379-89.
23. Lairez O, Delmas C, Fournier P, et al. Feasibility and accuracy of gated blood pool SPECT equilibrium radionuclide ventriculography for the assessment of left and right ventricular volumes and function in patients with left ventricular assist devices. *J Nucl Cardiol* 2016. [Epub ahead of print]