MODULE APPAREIL NEUROSENSORIEL

DFGSM 2 2022-2023

IMAGERIE METABOLIQUE ET MOLECULAIRE CEREBRALE SPECT ET PET

Objectif de connaissances, item 108 - Confusion, démences (voir item 132)
Rang B : Connaitre les indications des examens de médecine nucléaire dans les démences

Connaitre les indications des examens de médecine nucléaire dans les démences 2C-108-EC-B04

Fiche LiSA

Validée

Objectif de connaissance	
Identifiant	2C-108-EC-B04
Item parent	Confusion, démences (voir item 132)
Rang	B
Intitulé	Connaitre les indications des examens de médecine nucléaire dans les démences
Description	Scingraphie de perfusion cérébrale, scintigraphie des transporteurs de la Dopamine, TEP au 18FDG
Rubrique	08-Examens complémentaires
Contributeurs	
Ordre	17

Indications **(demande d'un examen d'imagerie)** de la scintigraphie de perfusion ou de la Tomographie par Emission de Positons au FluoroDéoxyGlucose (TEP-FDG) dans les troubles neurocognitifs : toutes les **formes de diagnostic difficile** :

- patients vus au stade débutant de TNC mineur
- profil clinique atypique
- démence à début précoce.

L'hypoperfusion identifiée par la scintigraphie de perfusion et l'hypométabolisme mis en évidence par la TEP-FDG ont la même topographie :

- dans la maladie d'Alzheimer : hypoperfusion/hypométabolisme des régions corticales associatives et temporales internes (cf item 132 question diagnostic positif de la MA)
- dans les dégénérescences lobaires frontotemporales (DLFT) : hypoperfusion/hypométabolisme dans les régions frontales, temporales antérieures et/ou cingulaires (cf item 132 question Dégénérescence lobaire fronto-temporale)

Indication **(demande d'un examen d'imagerie)** de la scintigraphie des transporteurs de la Dopamine dans les troubles neurocognitifs : hésitation diagnostique entre une maladie à corps de Lewy diffus (examen pathologique objectivant une dénervation dopaminergique du striatum) et une maladie d'Alzheimer (examen normal). (cf item 132 question Maladie à corps de Lewy)

Catégorie : Objectif de connaissance

INDICATIONS PRINCIPALES

- EPILEPSIES PHARMACORESISTANTES
  - Recherche de foyer
  - HMPAO ou ECD per et inter-critique
- Syndromes PARKINSONNIENS (ioflupane)
  - Tremblement essentiel versus PK
  - Alzheimer versus Démence à corps de Lewy diffus
- TUMEURS CEREBRALES
  - FDG (radionécrose versus récidive)
  - Thallium, FET,…
- DIAGNOSTIC DE DEMENCES
  - Dégénératives, vasculaires, Hydrocéphalie, Trauma
  - FDG préféré à ECD ou HMPAO, Plaques amyloïdes

RADIOTRACEURS DISPONIBLES

- PERFUSION:
  - ^{99m}Tc-ECD/HMPAO

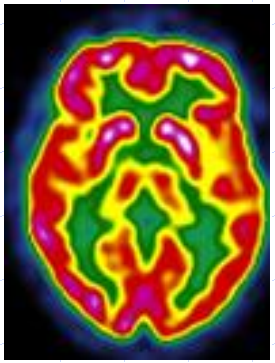

- METABOLISME:
  - Neuronal: ^{18}F-DG, ^{210}Tl
  - Dopamine :
    - Synthèse dopa: ^{18}F-DOPA
    - Recapture dopamine: ^{123}I-FP-CIT (ioflupane = Datscan®)
  - Plaques amyloïdes et protéine tau (18F) :

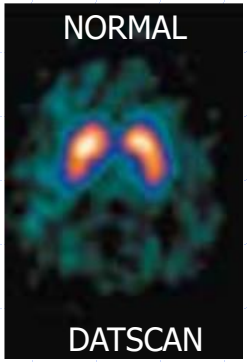

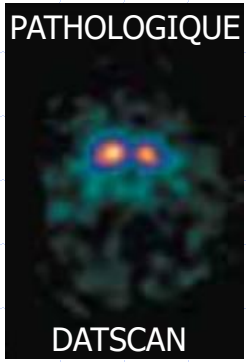

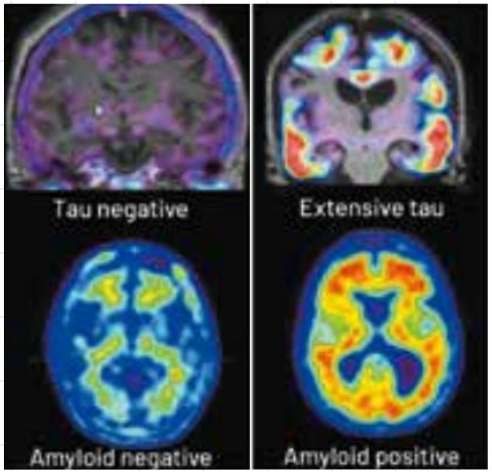

TEMP PERF ou TEP ^{18}F-DG NORMALE

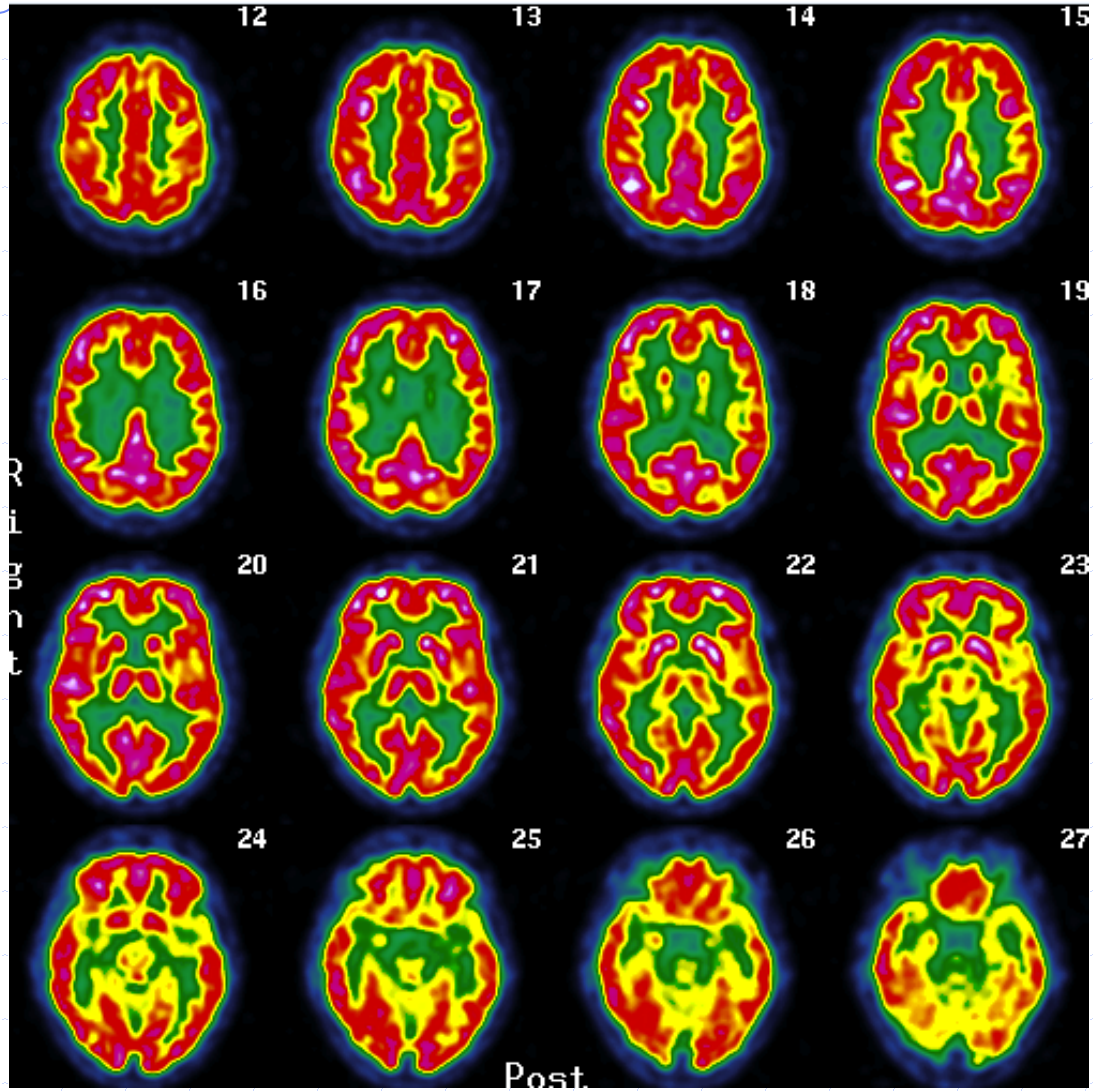

CHU VAL DE GRACE PARIS

EPILEPSIES (^{99m}Tc-HMPAO ou ECD)

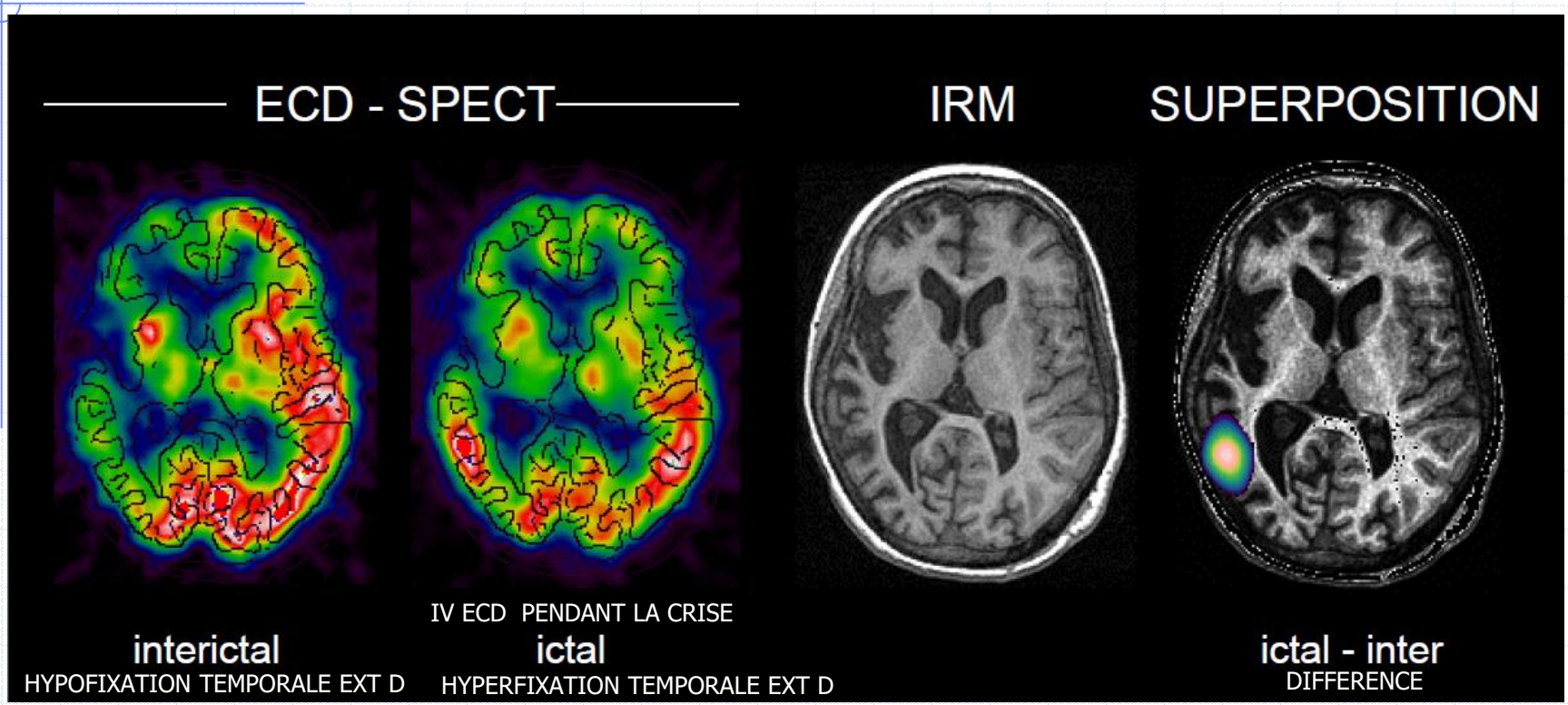

TUMEURS (^{201}Tl)

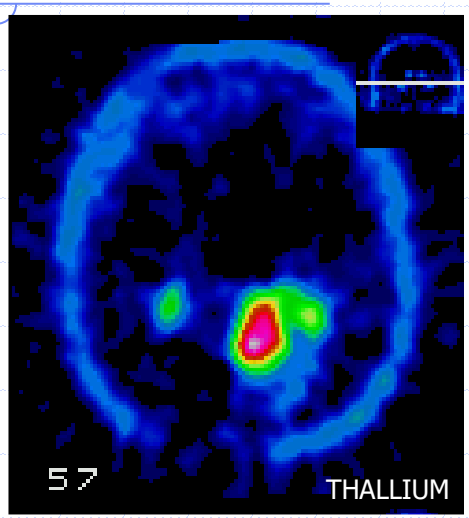

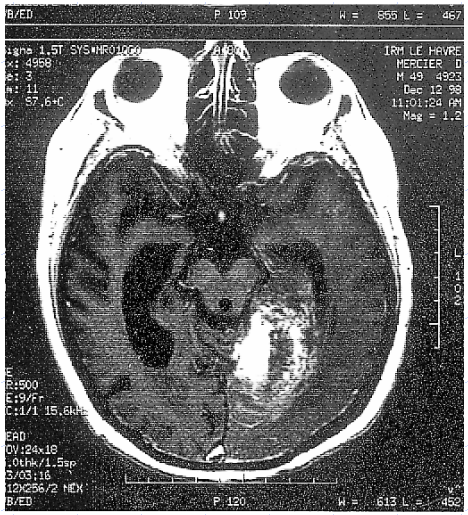

Le thallium est un radiotraceur de l'agressivité de certaines tumeurs cérébrales

CHU ROUEN

Sd PARKINSONIENS

= ^{123}I-IOFLUPANE (DATSCAN) / ^{18}FDOPA

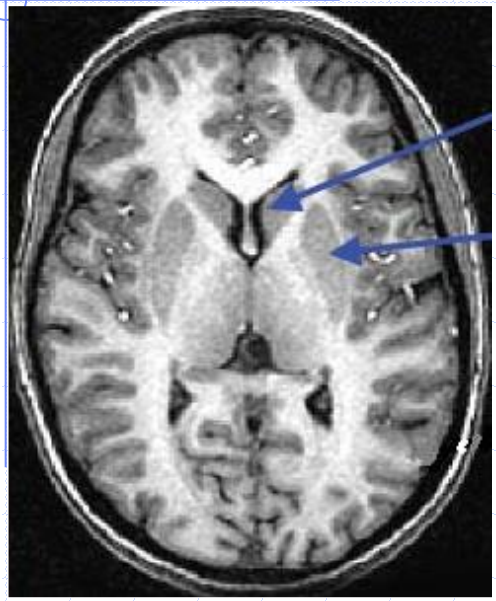

TETE DU NOYAU CAUDE

PUTAMEN

STRIATUM

L'ioflupane trace la fonction des récepteurs présynaptiques de la dopamine dans les striata. Cette fonction est altérée dans la maladie de Parkinson et les syndromes parkinsoniens.

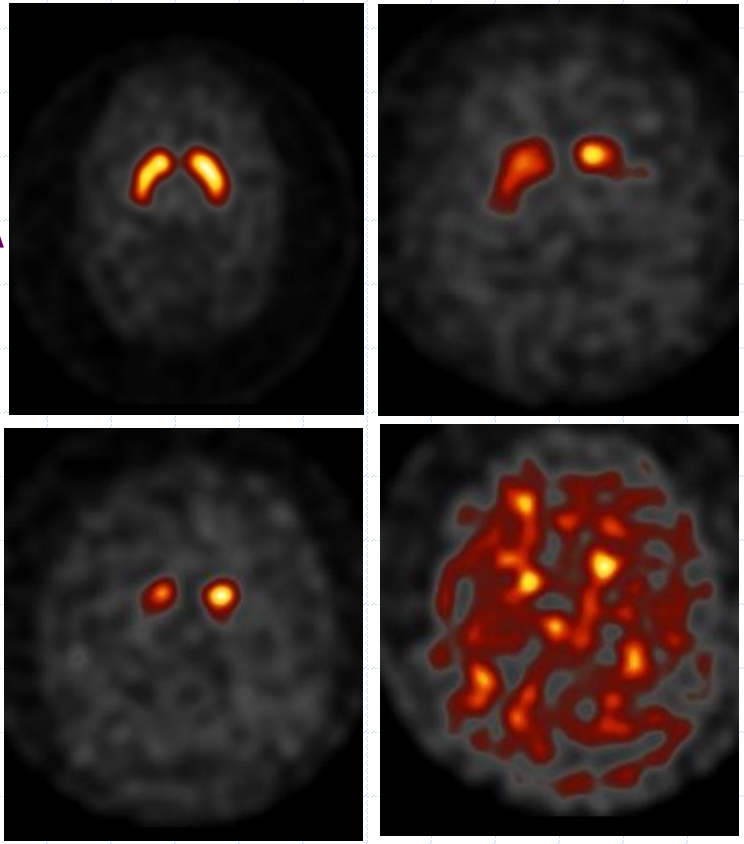

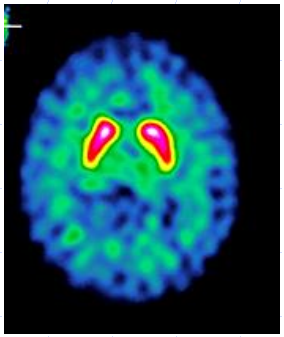

NORMAL

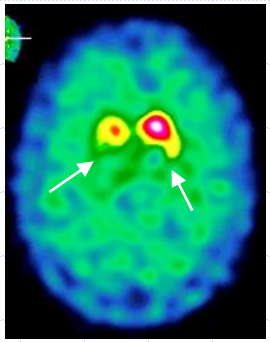

PARKINSON

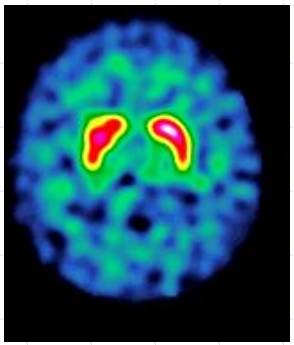

NORMAL CHEZ ALZHEIMER

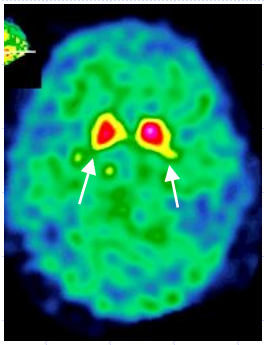

DEMENCE A CORPS DE LEWY

0. Slide de connexion

Cliquez sur l'écran projeté pour lancer la question

Copier le lien de participation

Allez sur **www.wooclap.com** et utilisez le code **NEUROISOTOP**

Où se trouvent les hypométabolismes pathologiques du FDG dans cette image ?

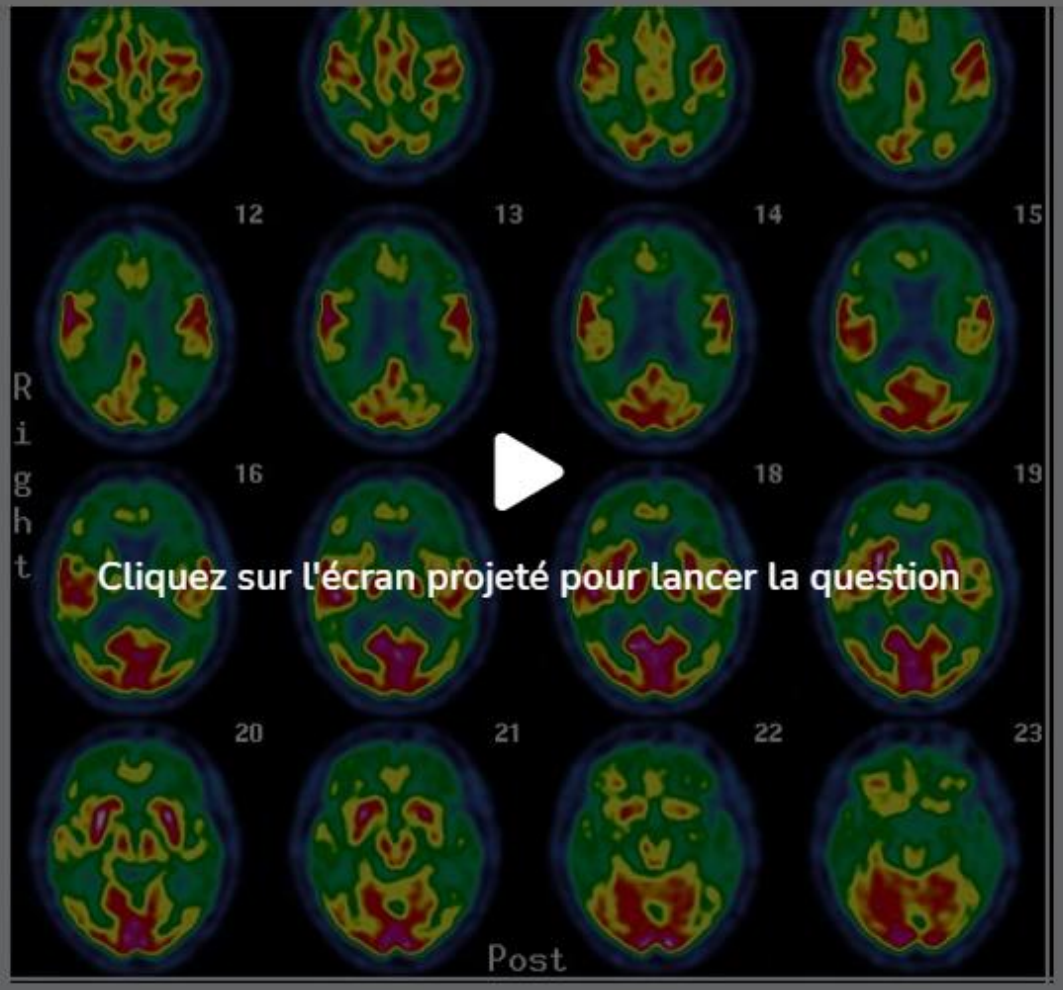

Cliquez sur l'écran projeté pour lancer la question

wooclap
100 %
0

LE DEMENCES PRIMAIRES

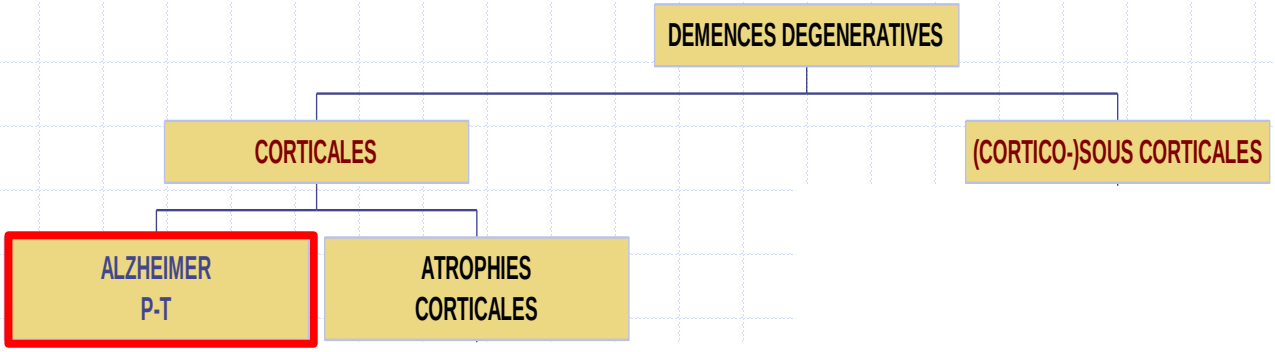

Maladie d'Alzheimer :

Accumulation de protéines β-amyloïdes et tau

Mémoire épisodique
Aphasie, apraxie, agnosie

ALZHEIMER

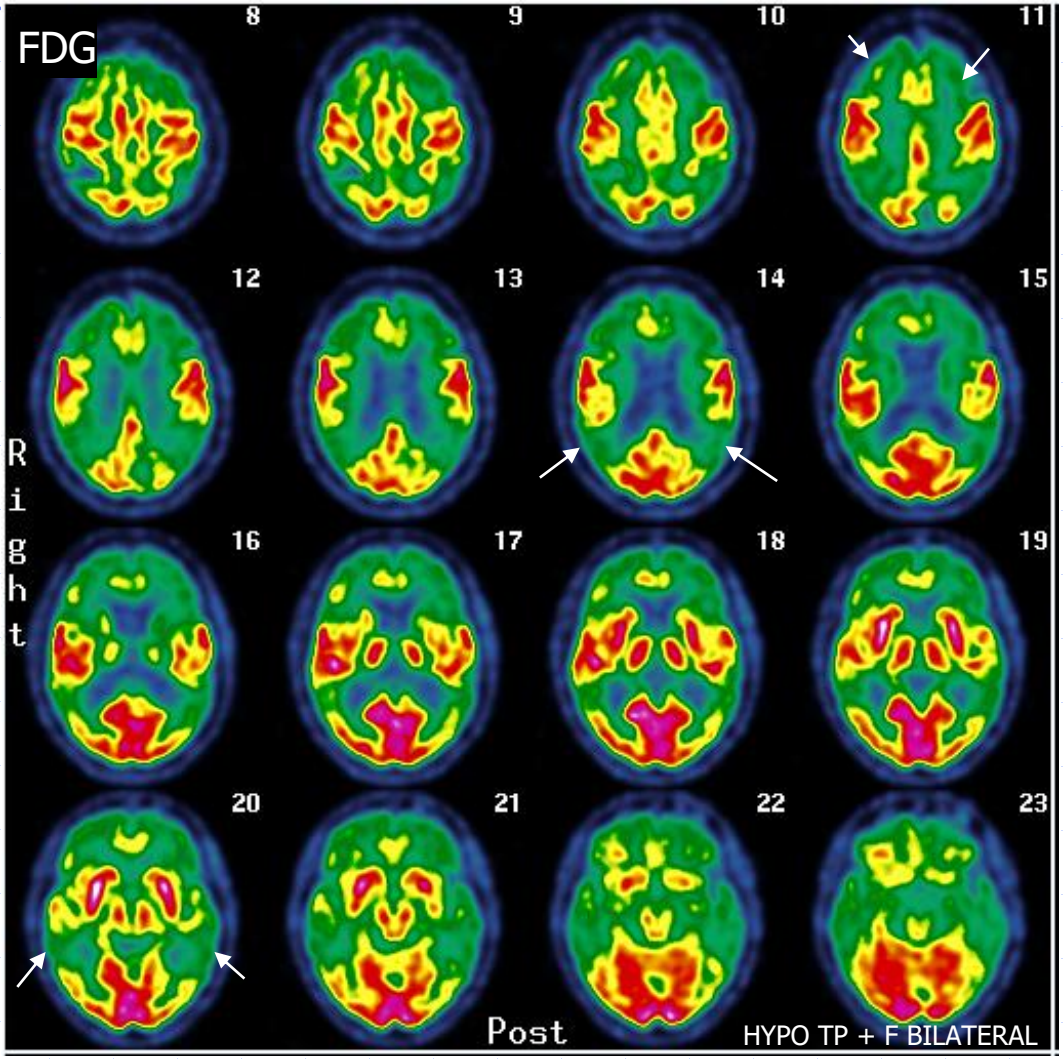

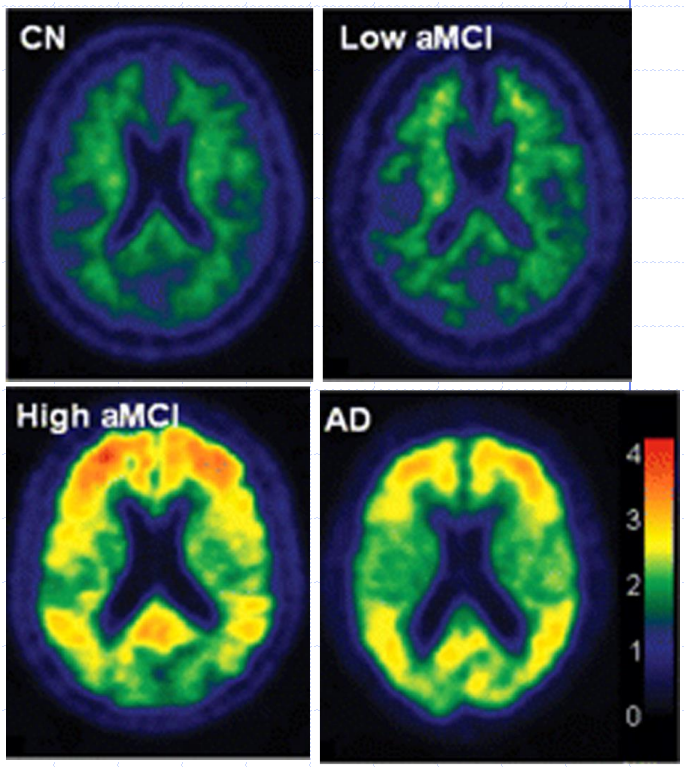

F-PLAQUES AMYLOIDES

Altérations : Pariétal &Temporal

Aires primaires, occipital, NGC, cervelet normaux

CHU PITIE PARIS

Kemppainen et al., Neurology 2007

ALZHEIMER

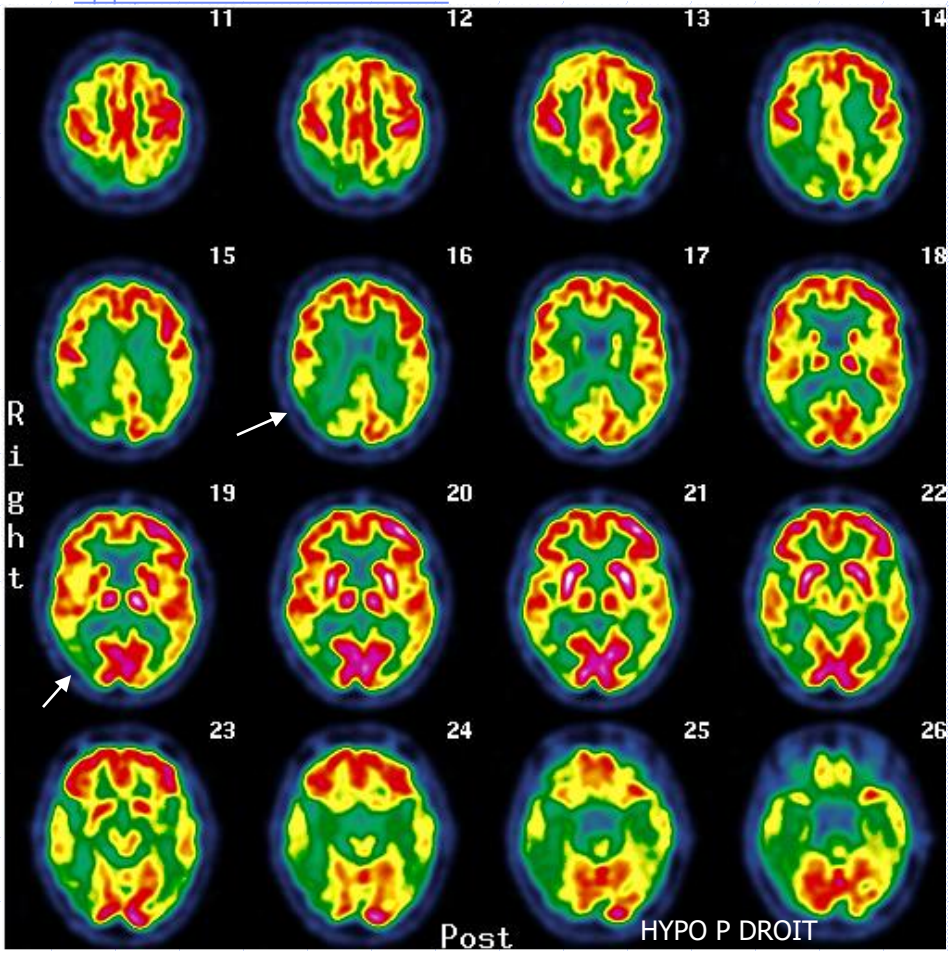

FDG: METABOLISME CEREBRAL DU GLUCOSE

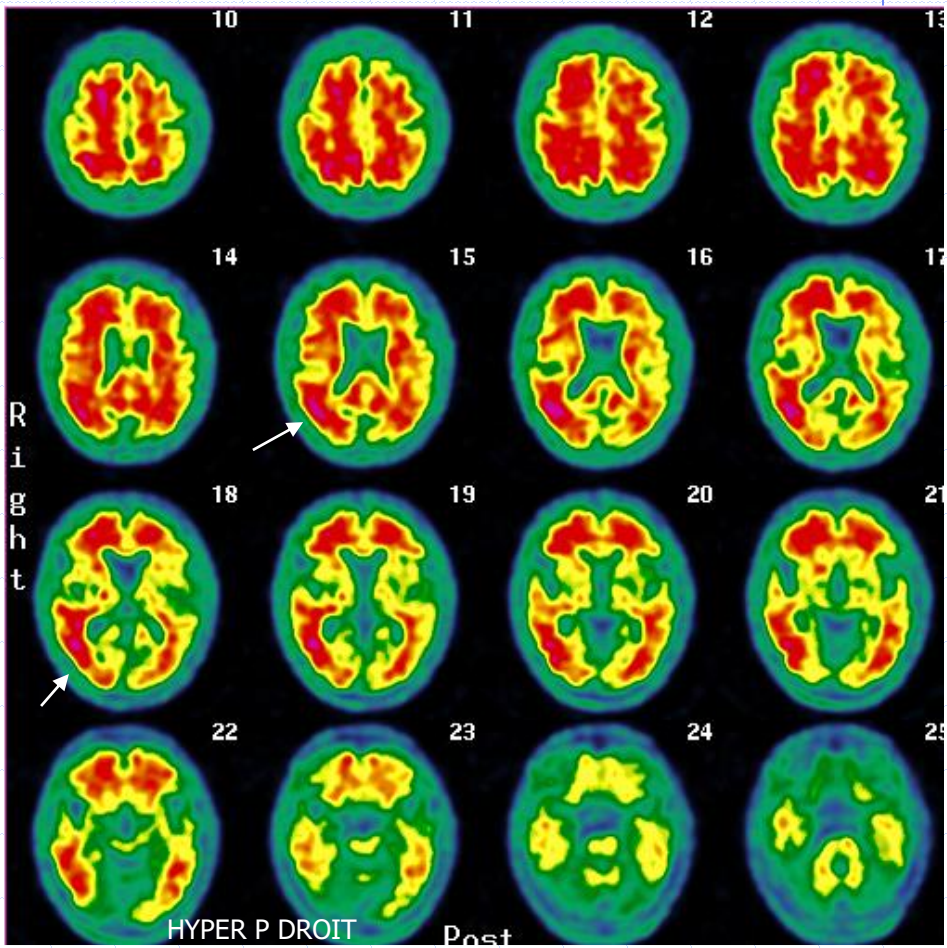

F-FLORBETAPIR: ACCUMULATION DE PLAQUES AMYLOIDES

CHU VAL DE GRACE PARIS

LE DEMENCES PRIMAIRES

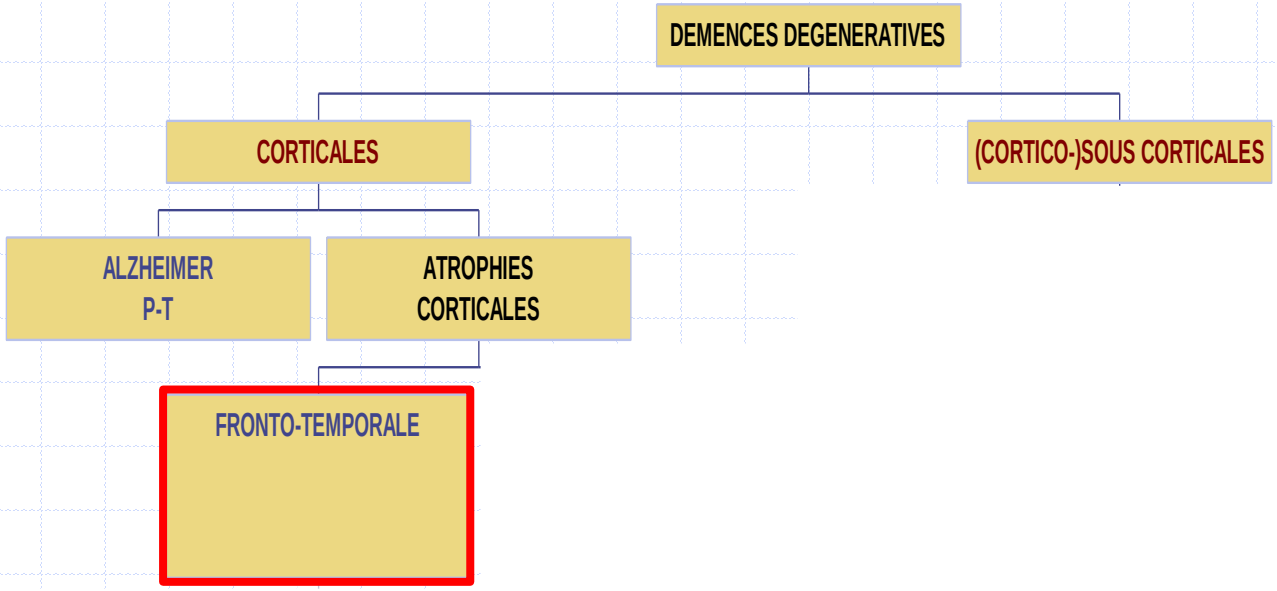

F: FRONTAL T: TEMPORAL P: PARIETAL O: OCCIPITAL NGC: NOYAUX GRIS CENTRAUX

DEMENCE FRONTO TEMPORALE

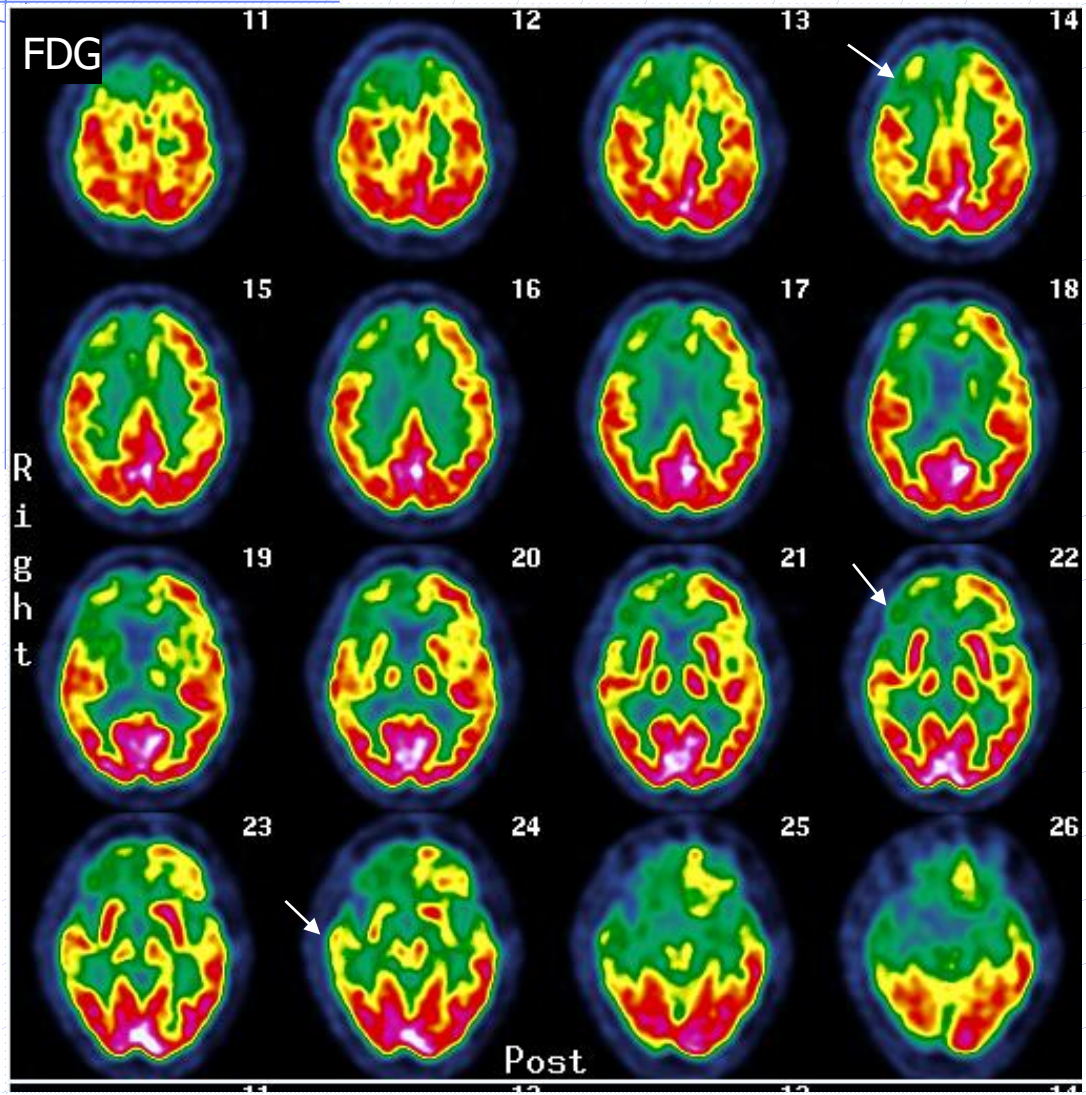

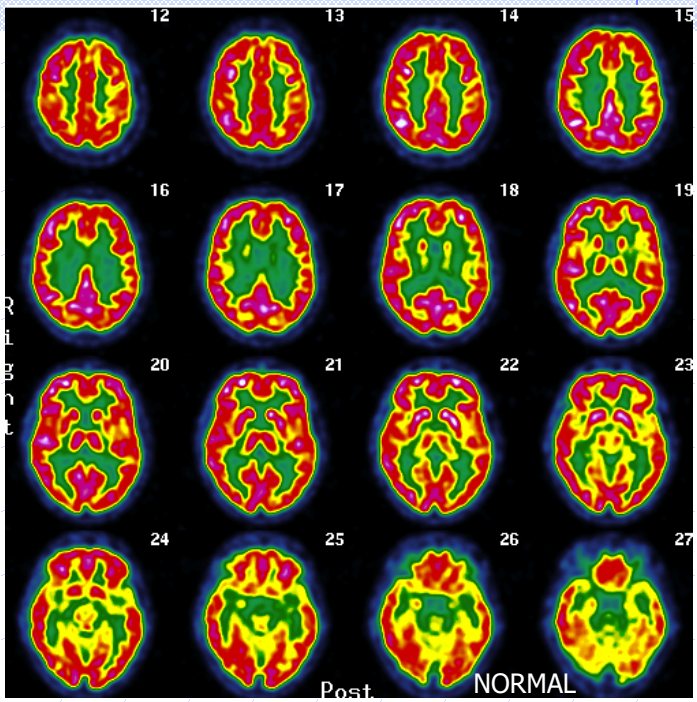

Altérations: Fronto-temporales

DFT :

Accumulation de Prot τ

Désinhibition, hyperoralité
Apathie, rituels, troubles exécutifs

CHU PITIE PARIS

LE DEMENCES PRIMAIRES

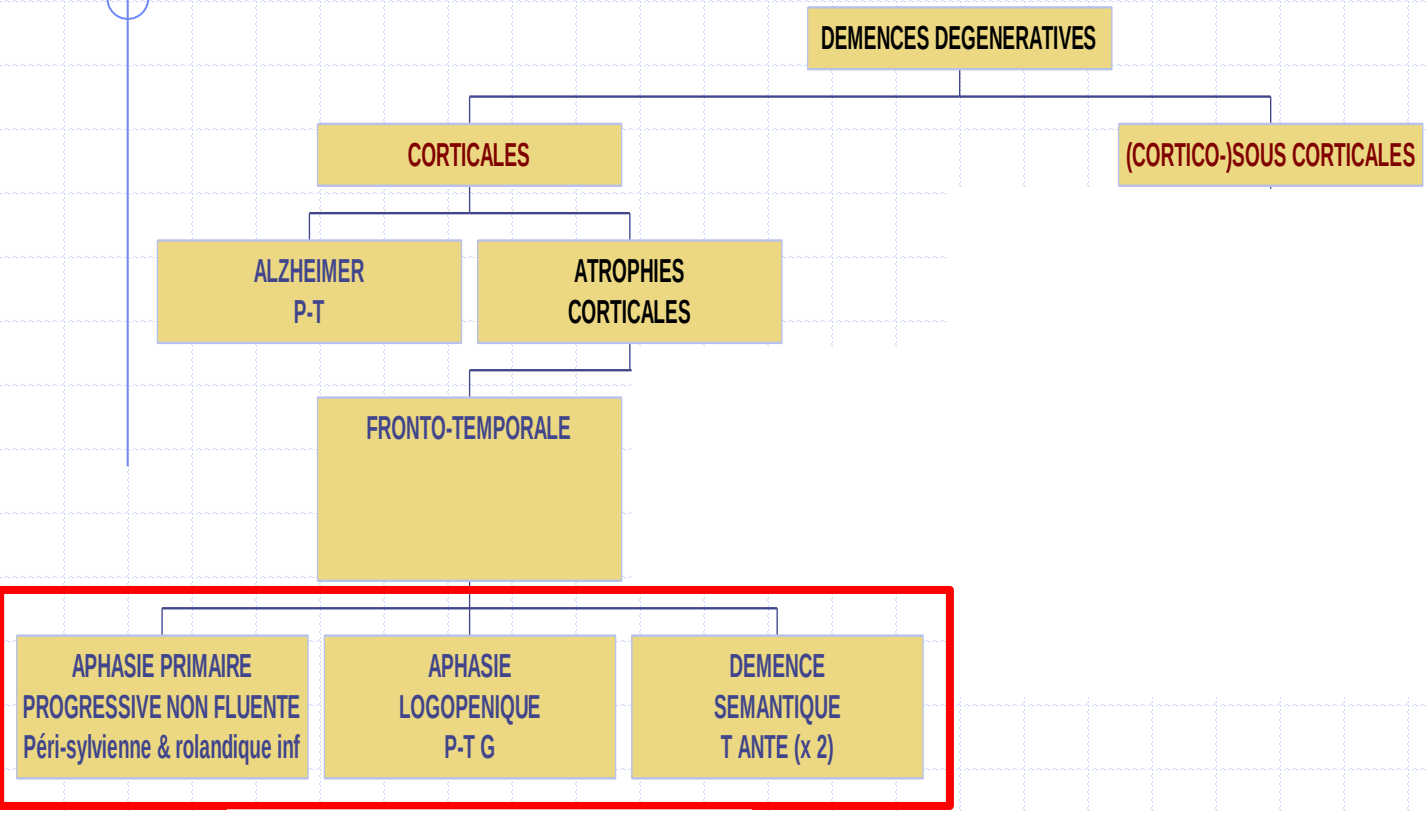

APHASIES PRIMAIRES PROGRESSIVES

F: FRONTAL T: TEMPORAL P: PARIETAL O: OCCIPITAL NGC: NOYAUX GRIS CENTRAUX

APP NON FLUENTE

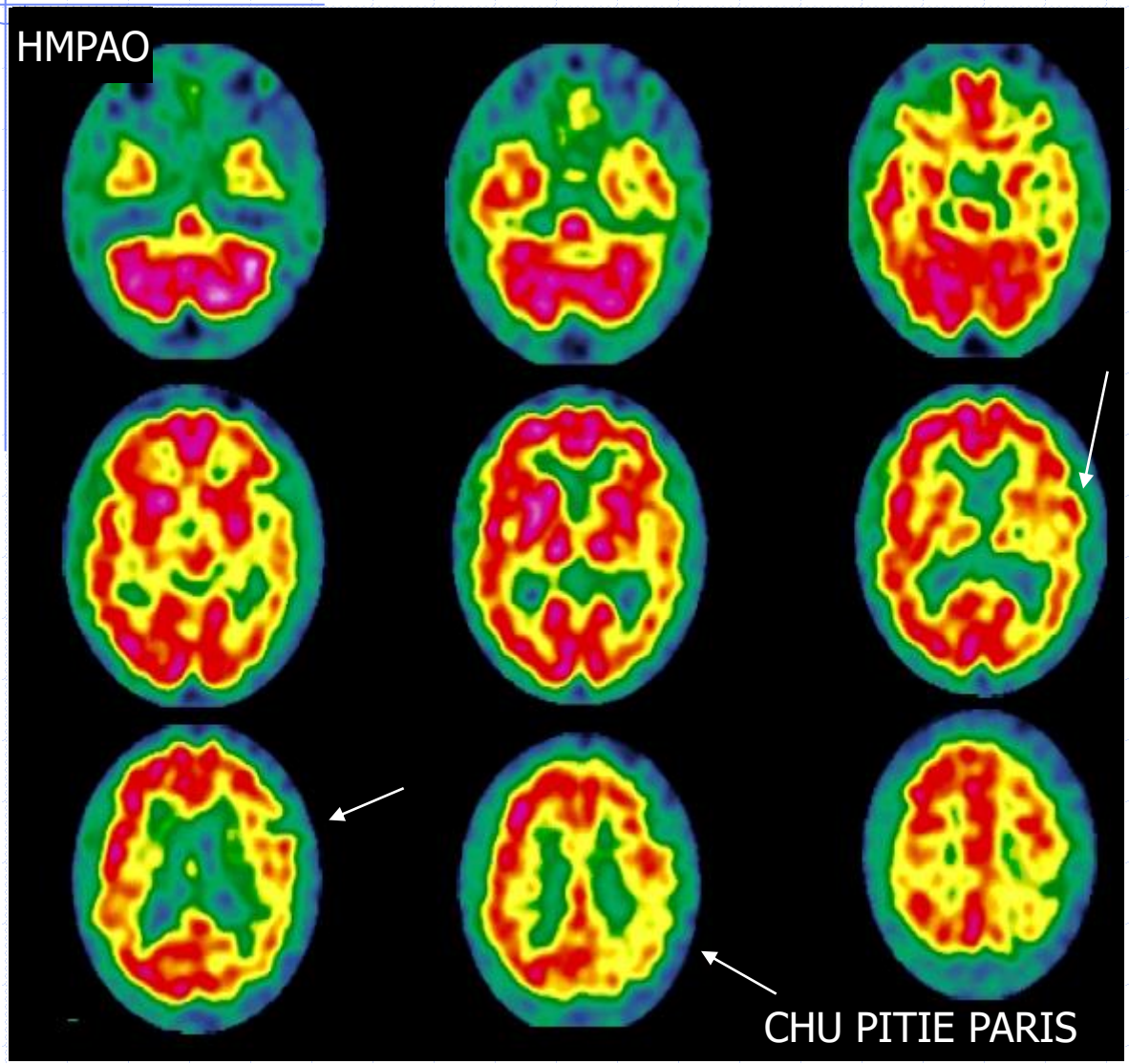

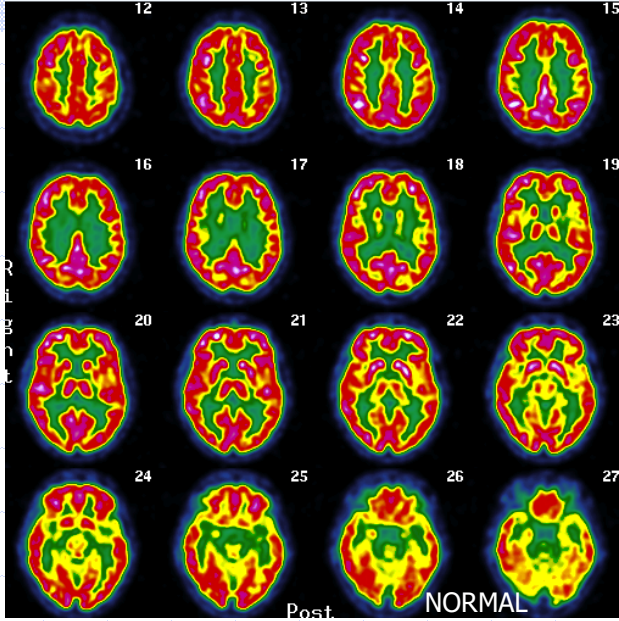

Altérations:

Sylvienne G péri-rolandique

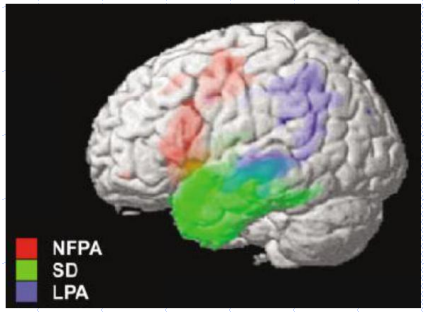

APP NF :

Accu. de prot. τ

Elocution, agrammatisme

Compréhension de phrases complexes

APP LOGOPENIQUE

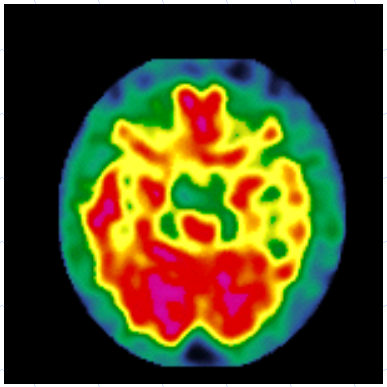

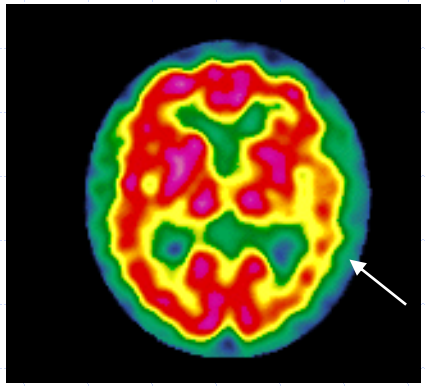

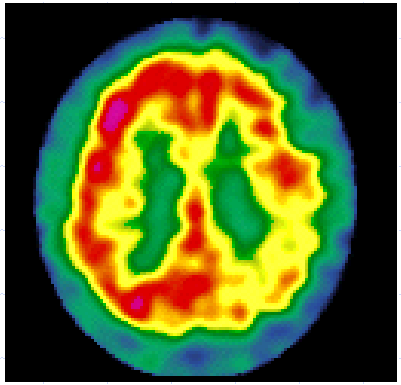

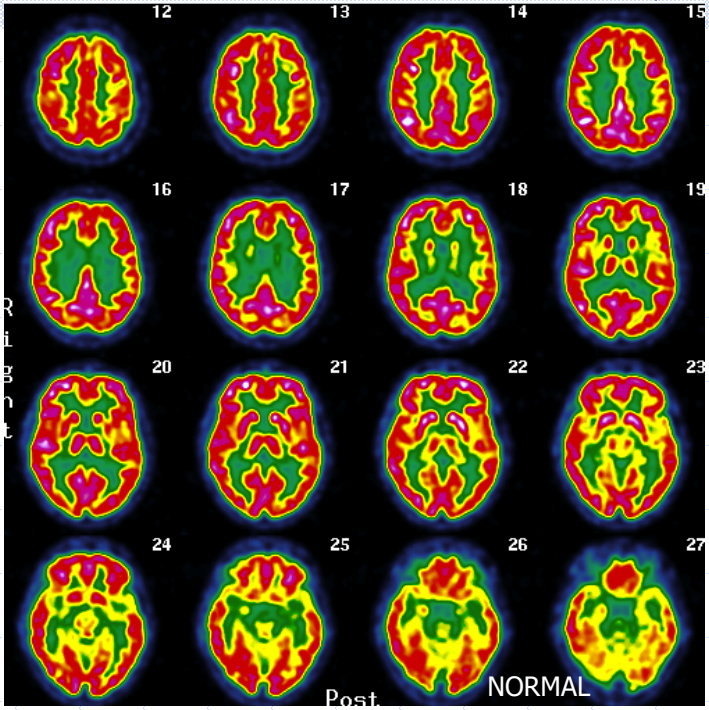

Altérations : Temporo-Pariétal G (peri-sylvienne postérieure) + associatif post G

APP L :

Forme de MA

Manque du mot
Troubles de la répétition
Paraphasie phonémique

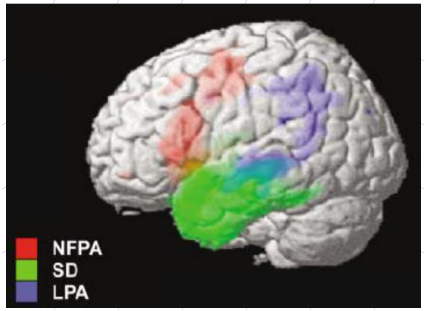

APP SEMANTIQUE

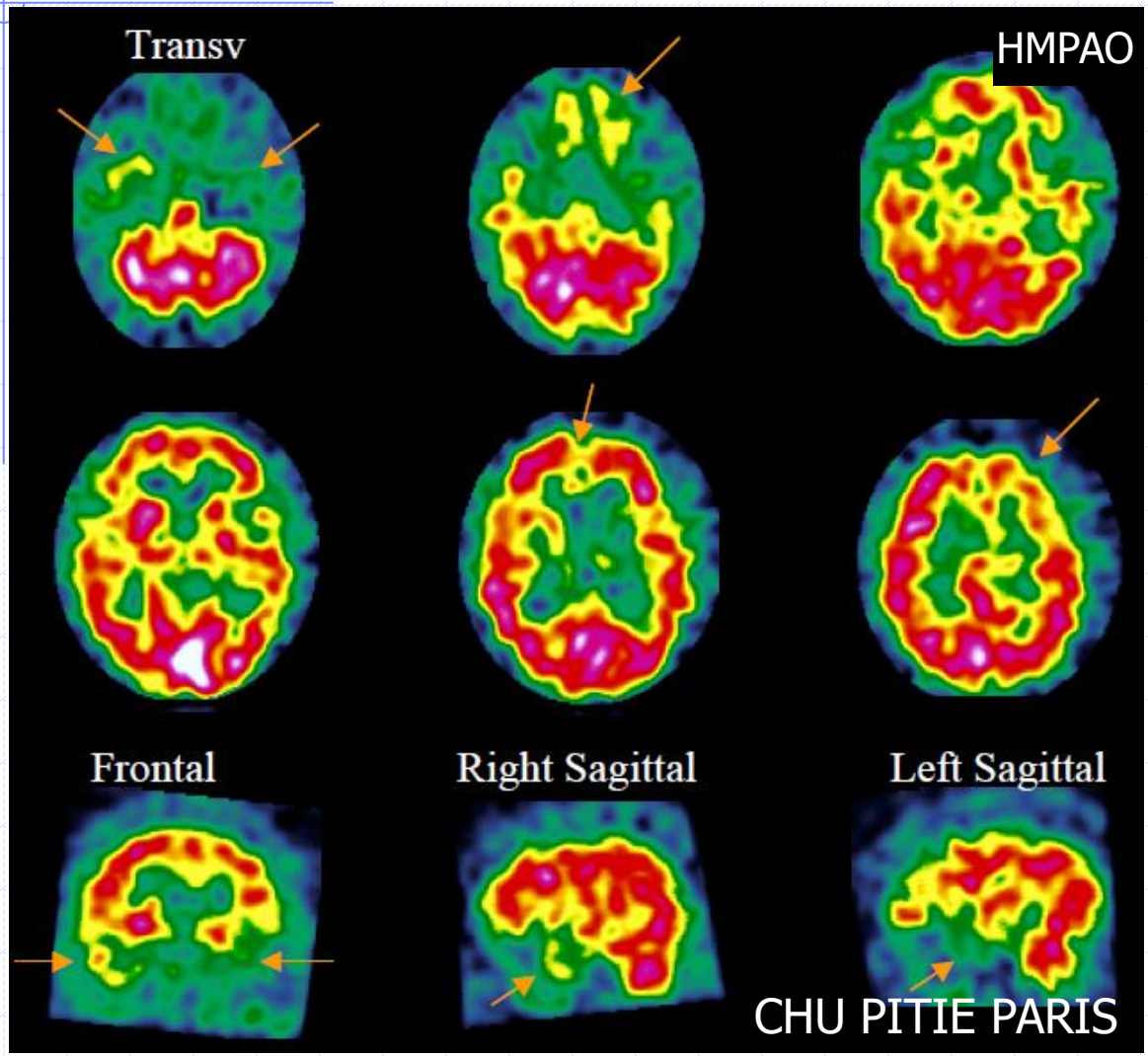

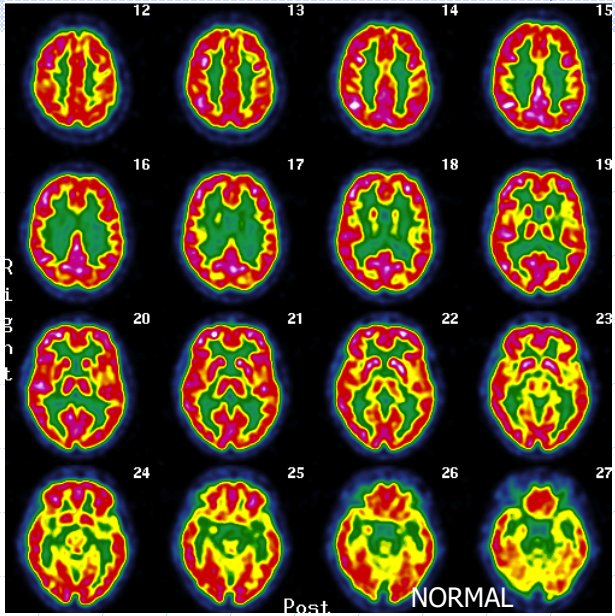

Altérations :

Temporal antérieur g

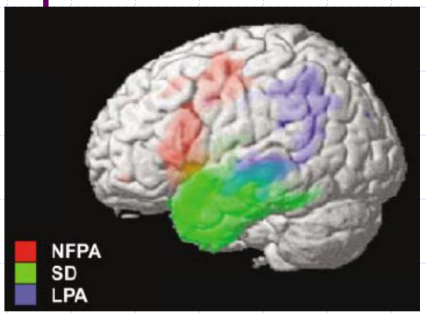

APPS :

Accu. prot. TPD-43

Manque du mot en dénomination
Troubles de la compréhension
Connaissance personnes/concepts
Dyslexie, dysgraphie

LE DEMENCES PRIMAIRES

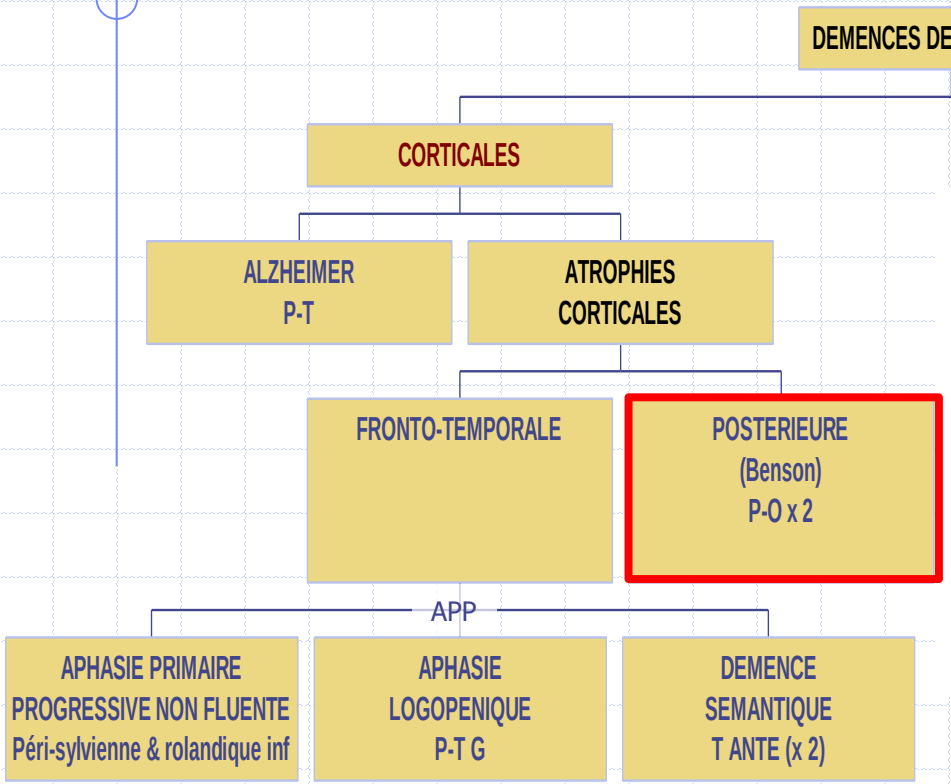

F: FRONTAL T: TEMPORAL P: PARIETAL O: OCCIPITAL NGC: NOYAUX GRIS CENTRAUX

ATROPHIE CORTI-CALE POSTERIEURE

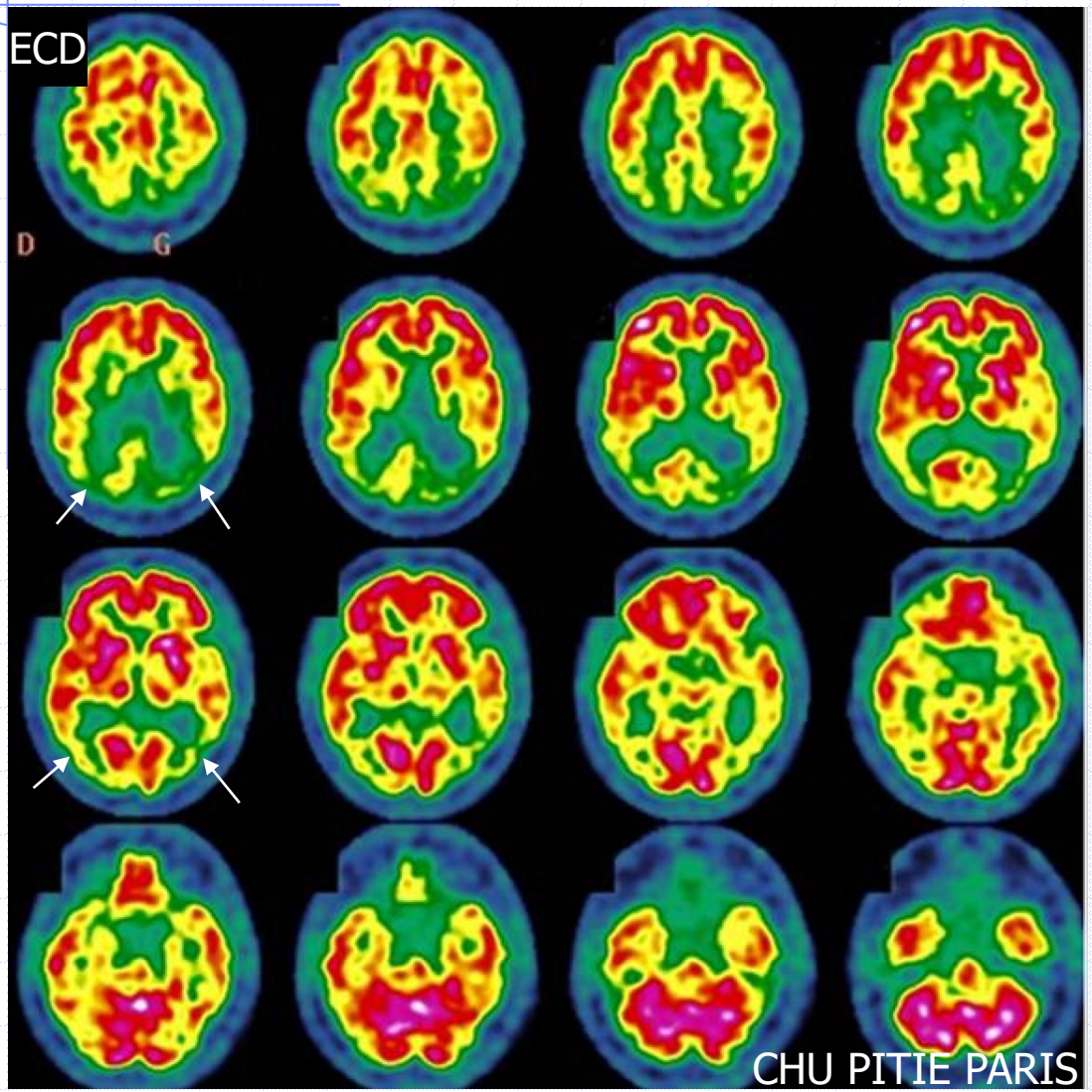

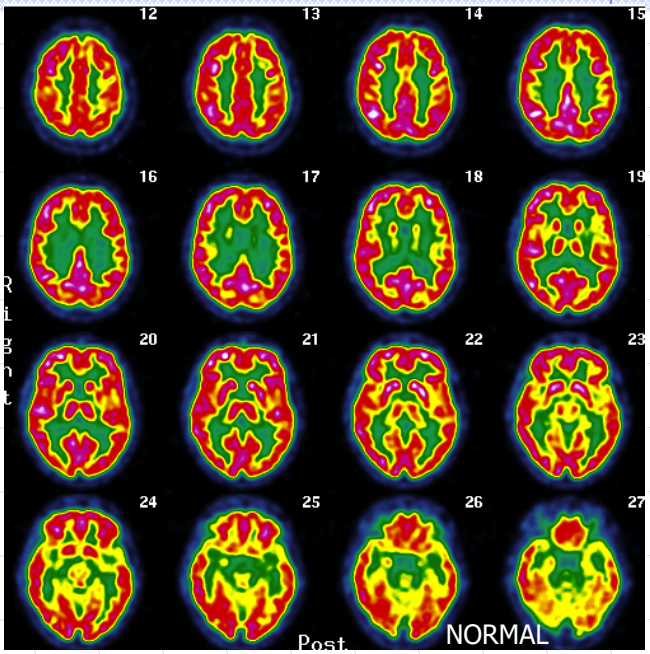

Altérations: Pariéto-occipital x2

ACP :

Forme de MA

Plainte visuelle,

S de Balint: apraxie/ataxie optique + simultagnosie

S de Gertsmann (agnosie digitale, indistinction D/G, dyscalculie, dysgraphie)

LE DEMENCES PRIMAIRES

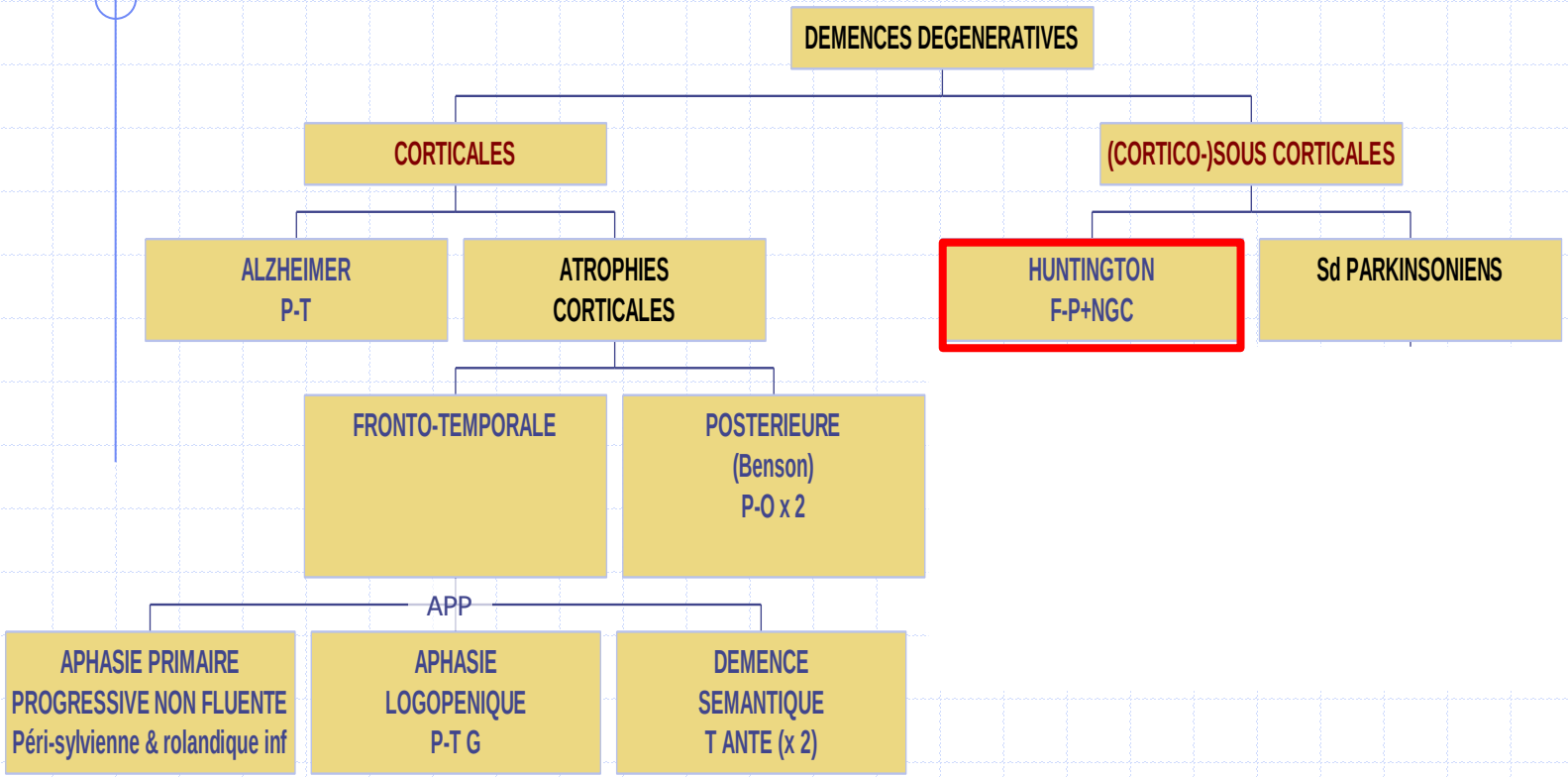

F: FRONTAL T: TEMPORAL P: PARIETAL O: OCCIPITAL NGC: NOYAUX GRIS CENTRAUX

HUNTINGTON

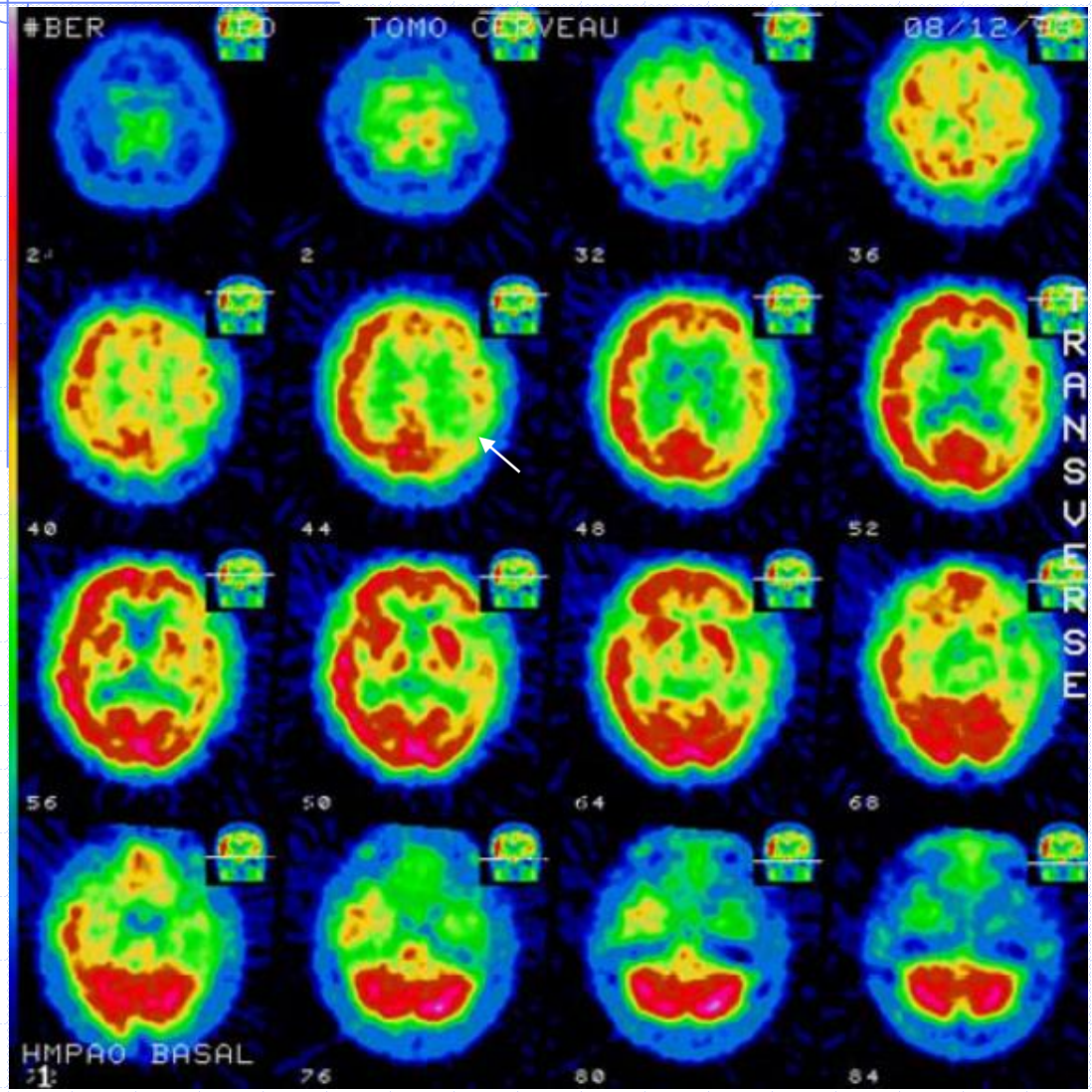

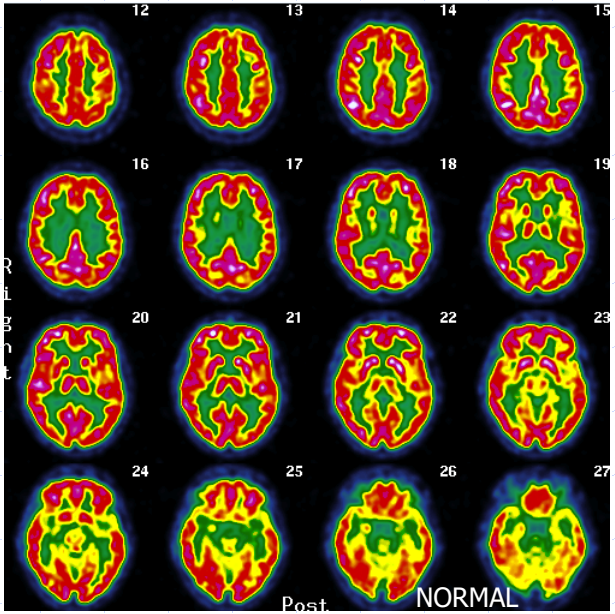

Altérations : NGC + Fronto-Pariétal

CHU PITIE PARIS

LE DEMENCES PRIMAIRES

- DEMENCES DEGENERATIVES
  - CORTICALES
    - ALZHEIMER
      P-T
    - ATROPHIES CORTICALES
      - FRONTO-TEMPORALE
      - POSTERIEURE
        (Benson)
        P-O x 2
      - APP
        - APHASIE PRIMAIRE PROGRESSIVE NON FLUENTE
          Péri-sylvienne & rolandique inf
        - APHASIE LOGOPENIQUE
          P-T G
        - DEMENCE SEMANTIQUE
          T ANTE (x 2)
  - (CORTICO-)SOUS CORTICALES
    - HUNTINGTON
      F-P+NGC
    - Sd PARKINSONIENS
      - DEGENERESCENCE CORTICO-BASALE
        F-P+NGC
      - D CORPS DE LEWY DIFFUS
        P-T + O(I,II) + NGC
      - PARA SUPRANUCLEAIRE PROGRESSIVE (F+NGC)
        et
        ATROPHIE MULTI SYSTEMIQUE

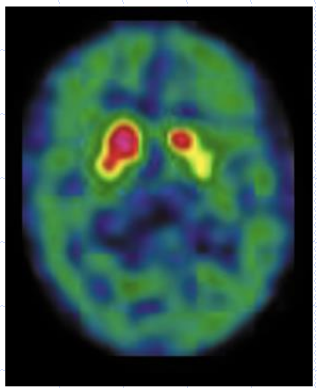
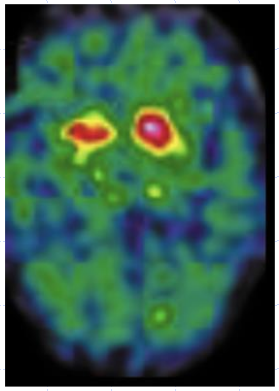
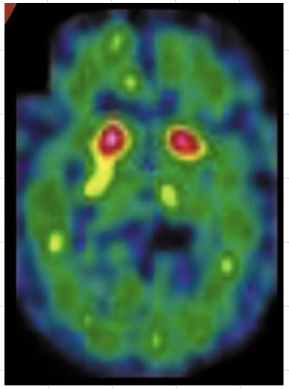

DAT-SCAN PATHOLOGIQUES

F: FRONTAL T: TEMPORAL P: PARIETAL O: OCCIPITAL NGC: NOYAUX GRIS CENTRAUX

DEGENESCENCE CORTICOBASALE

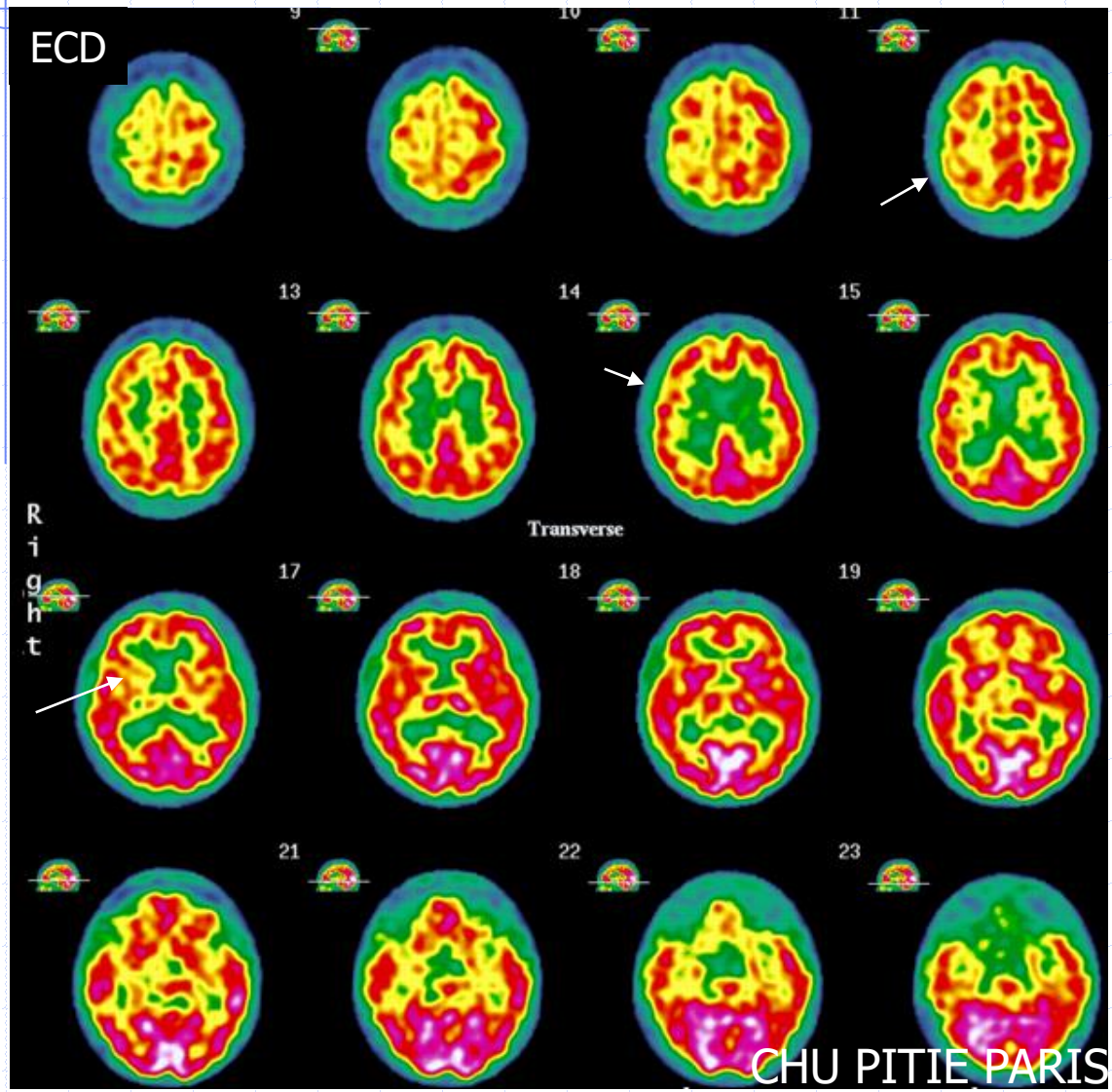

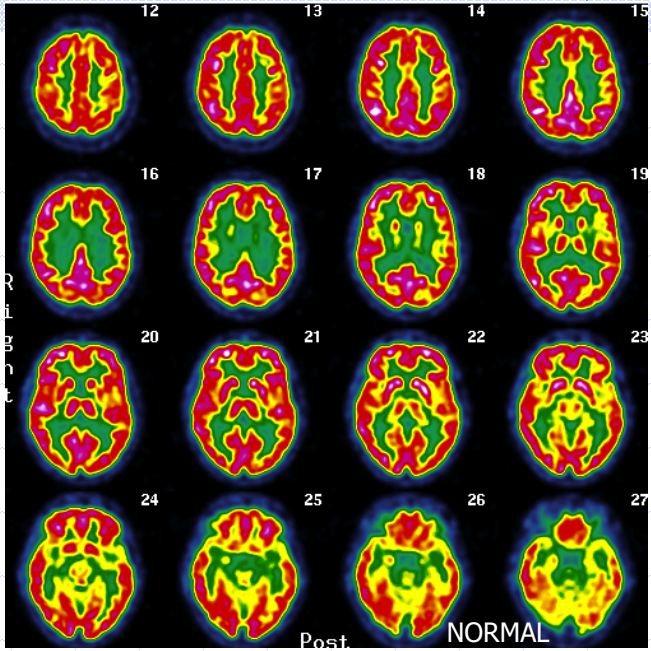

Altérations : NGC +
Frontal post + Pariétal unilat

DCB :
Accu. de Prot. τ
Syndrome PK
Apraxie
(Troubles sensitifs, membre étranger)

DEMENCE A CORPS DE LEWY

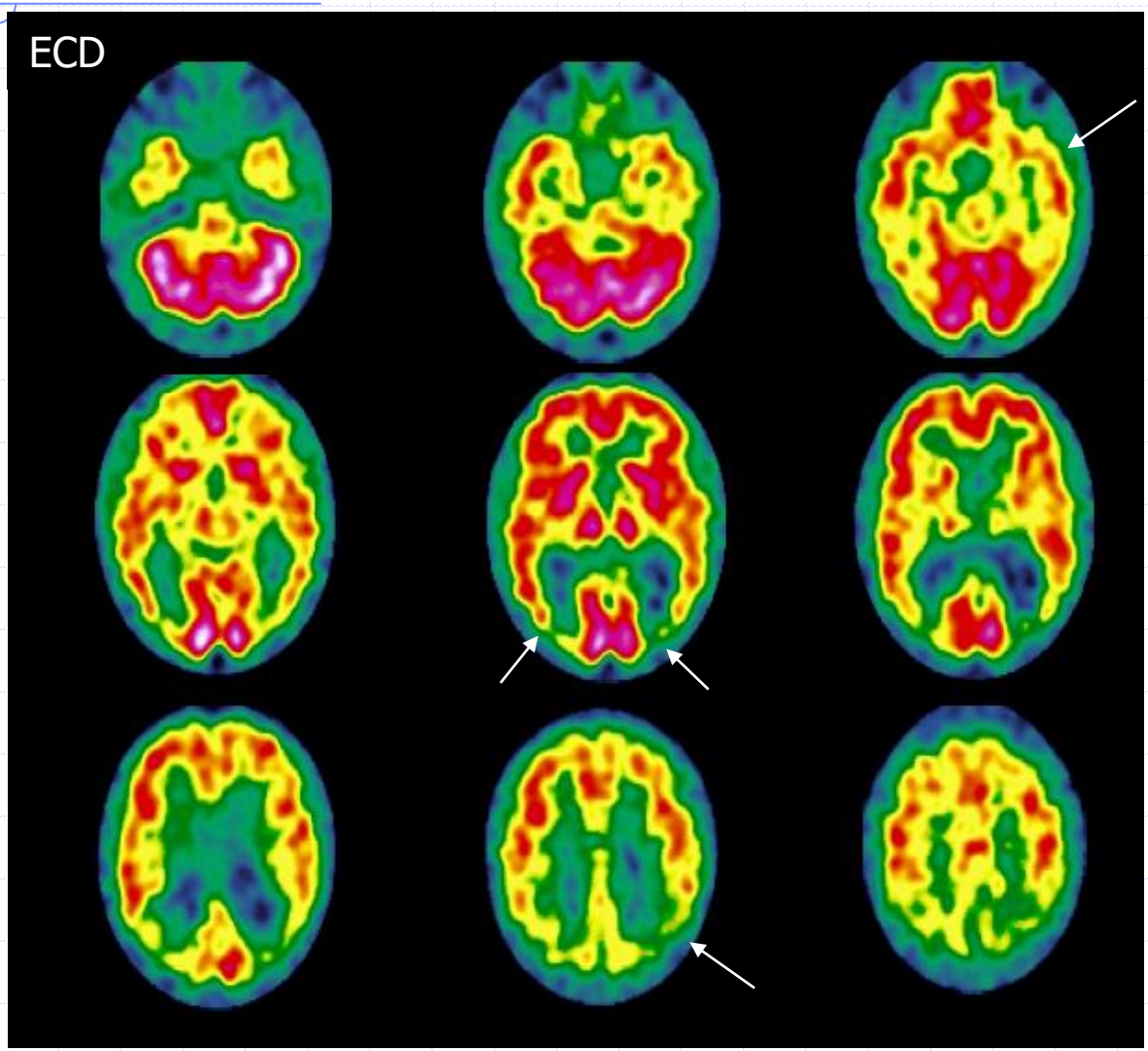

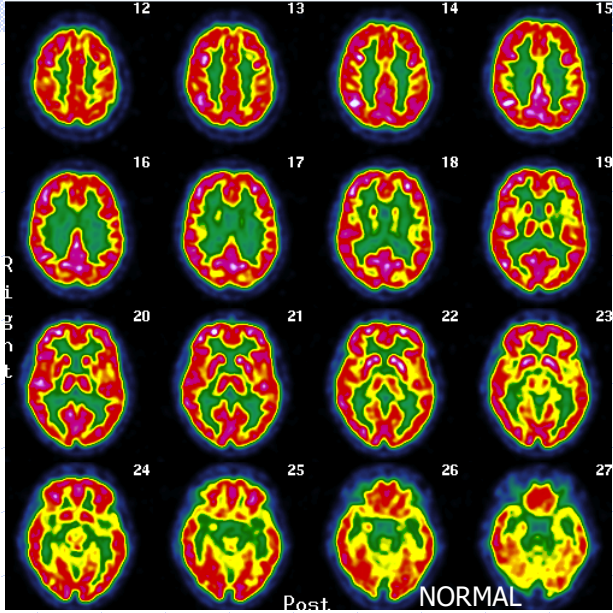

Altérations :
≈ MA + Occipital
+/- NGC

DCL : Accu. de corps de Lewy + prot. β amyloïde

Syndrome PK + cognitif
Hallucinations, comportement

CHU PITIE PARIS

PARALYSIE SUPRANU-CLEAIRE PROGRESSIVE

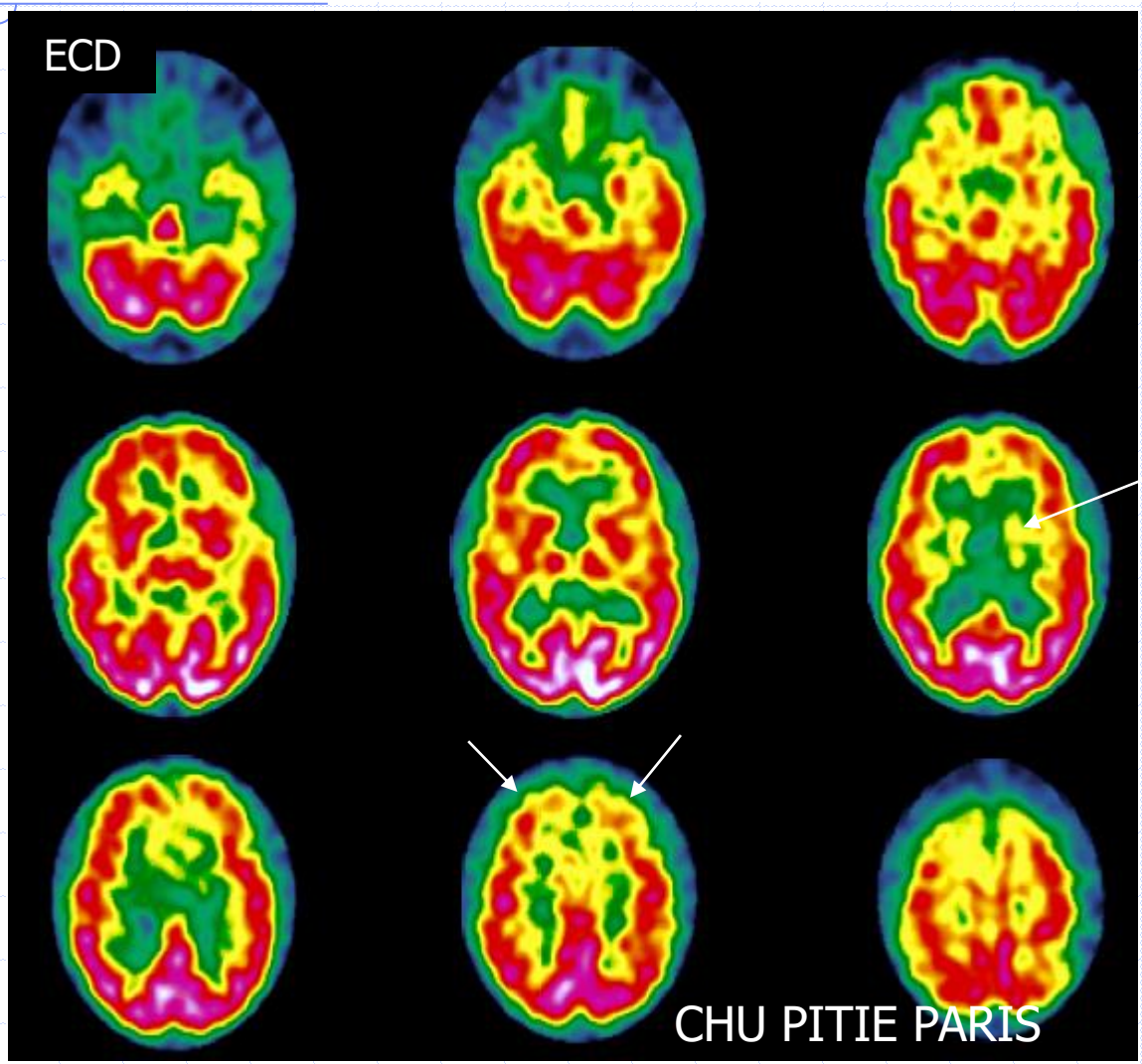

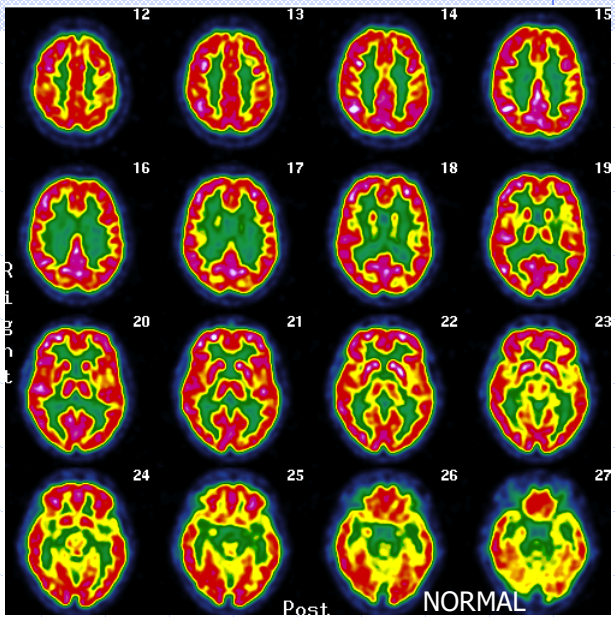

Altérations : NGC + Frontal

PSNP: Accu. prot. τ

Syndrome PK
Mvt oculaires verticaux
(ophtalmoplégie supranucléaire)
Apathie, ralentissement

LE DEMENCES PRIMAIRES

- DEMENCES DEGENERATIVES
  - CORTICALES
    - ALZHEIMER
    - ATROPHIES CORTICALES
      - FRONTO-TEMPORALE
        - APP
          - APHASIE PRIMAIRE PROGRESSIVE NON FLUENTE Péri-sylvienne & rolandique inf
          - APHASIE LOGOPENIQUE P-T G
          - DEMENCE SEMANTIQUE T ANTE (x 2)
      - POSTERIEURE (Benson) P-O x 2
  - (CORTICO-)SOUS CORTICALES
    - HUNTINGTON F-P+NGC
    - Sd PARKINSONIENS NGC
      - DEGENERESCENCE CORTICO-BASALE F-P+NGC
      - D CORPS DE LEWY DIFFUS P-T + O(I,II) + NGC
      - PARA SUPRANUCLEAIRE PROGRESSIVE (F+NGC) et ATROPHIE MULTI SYSTEMIQUE

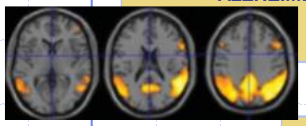

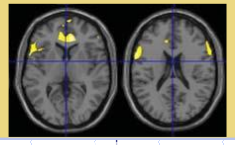

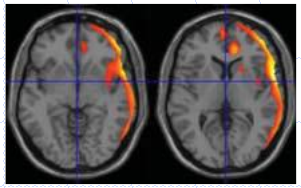

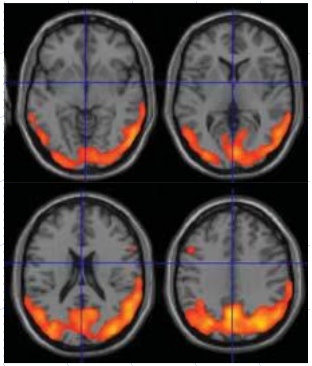

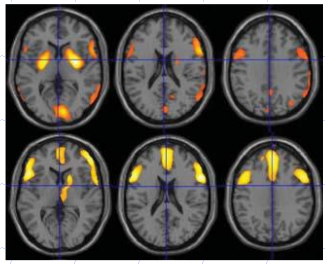

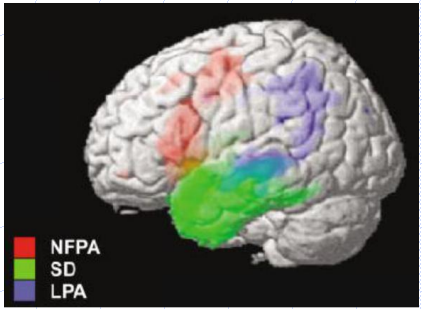

F: FRONTAL T: TEMPORAL P: PARIETAL O: OCCIPITAL NGC: NOYAUX GRIS CENTRAUX

SYNTHESE DEMENCES

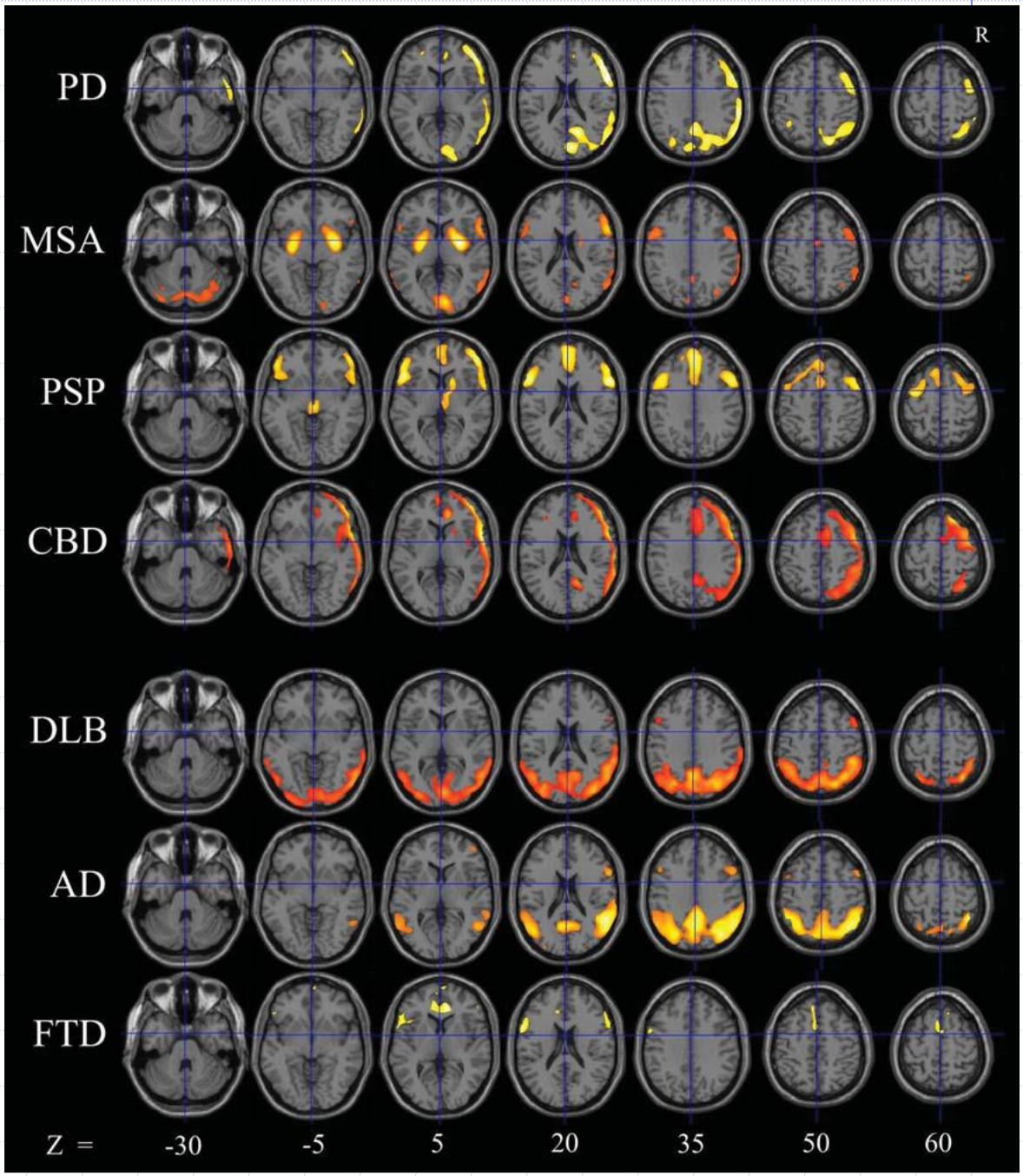

PD DEMENCE ASSOCIEE A UN PARKINSON
MSA ATROPHIE MULTISYSTEMIQUE
PSP PARALYSIE SUPRANUCLEAIRE PROGRESSIVE
CBD DEMENCE CORTICOBASALE
DLB DEMENCE A CORPS DE LEWY
AD DEMENCE DE TYPE ALZHEIMER
FTP DEMENCE FRONTO TEMPORALE

Typical Cerebral Metabolic Patterns in Neurodegenerative Brain Diseases. Teule & al. *Mvts dis. 2010*

MERCI POUR VOTRE ATTENTION

ORIGINE DES IMAGES ET REMERCIEMENTS

DEPARTEMENT DE MEDECINE NUCLEAIRE, CHU DE MONTPELLIER

MO HABERT, CHU PITIE SALPETRIERE, PARIS

E GONTIER & M BASELY, HIA VAL DE GRACE PARIS